

Listeria abdominal endograft infection miming pseudoaneurysm treated with *in-situ* aortic reconstruction: a case report

R. BERCHIOLLI¹, G. BERTAGNA¹, P.A. ERBA², M. FERRARI¹, N. TROISI¹

¹Vascular Surgery Unit, Department of Translational Research and New Technologies in Medicine and Surgery, University of Pisa, Pisa, Italy

²Unit of Nuclear Medicine (P.A.E.), Department of Translational Research and New Technologies in Medicine and Surgery, University of Pisa, Pisa, Italy

Abstract. – We report the case of a 72-year old man previously treated with an aortic endograft for an abdominal aortic aneurysm. After 3 years the patient developed a sepsis. Imaging and blood exams detected an endograft infection related to *Listeria monocytogenes*. Patients underwent endograft removal and *in-situ* aortic reconstruction with a cryopreserved allograft. A continuous antibacterial therapy has been established. One-month follow-up revealed the absence of clinically relevant infection with patency of the graft and absence of biochemical inflammatory markers.

Key Words:

Endograft infection, Allograft, *Listeria monocytogenes*, Vascular infection.

Introduction

Listeria monocytogenes is a gram-positive food borne pathogen causing listeriosis. It is a severe disseminating infection that mostly occurs in immunocompromised people. The pathogenetic mechanism includes the contact with the host, then the crossing into the intestinal wall at the level of Peyer's patches, the invasion of the mesenteric lymph nodes, and the spreading in all the human body throughout the blood¹.

The annual incidence of listeriosis in Europe is 0.34-0.52 per 100,000 people per year. In Italy, this rate is lower (0.19-0.27 per 100,000 people per year)². Sepsis is often present with a predominant involvement of the central nervous system.

Infections of vascular grafts, including endovascular devices have been reported³. Typical management of endograft infections consist of antibiotic therapy, and surgical treatment with

complete removal of both infected graft and aortic wall followed by *in-situ* reconstruction^{4,5}.

In this report we describe a case of abdominal aortic endograft infection caused by *Listeria monocytogenes* treated with *in-situ* reconstruction with a cryopreserved allograft.

The patient authorized the authors to describe the present case report.

Case Report

A 72-year old man was admitted to our outpatient clinic with a diagnosis of aortic pseudoaneurysm. His medical history was notable for hypertension, type 2 diabetes, and coronary artery disease. In addition, 3 years before the patient underwent an endovascular repair of a 55-mm abdominal aortic aneurysm (bifurcated aortic endograft, Excluder C3; W. L. Gore & Associates, Flagstaff, AZ, USA) at our surgical department.

Patient reported recurrent episodes of specific urological disorders (dysuria and strangury) without any other symptoms or signs, in particular fever. Despite treatment with oral administration of fluoroquinolones over 2 months⁶, symptoms persisted. Patient also complained a weight loss (8 kg in 2 months). Laboratory tests revealed a mild anemia (hemoglobin value 10.2 g/dL), a total white blood cell (WBC) count of 5.02 x 10³/microL (78.6% of neutrophils), procalcitonin value 0.11 ng/mL, C-reactive protein value 37.90 mg/L, creatinine serum level 0.98 mg/dL. A computed tomography (CT)-scan was firstly performed, revealing a bulging of unclear meaning on the right antero-lateral side of the aortic wall (Figure 1, left panel) and the diagnosis of aortic pseudoaneurysm was defined. Therefore, the patient was admitted to our department in order to identify and to clarify the origin of the bulging and to exclude endograft infection.

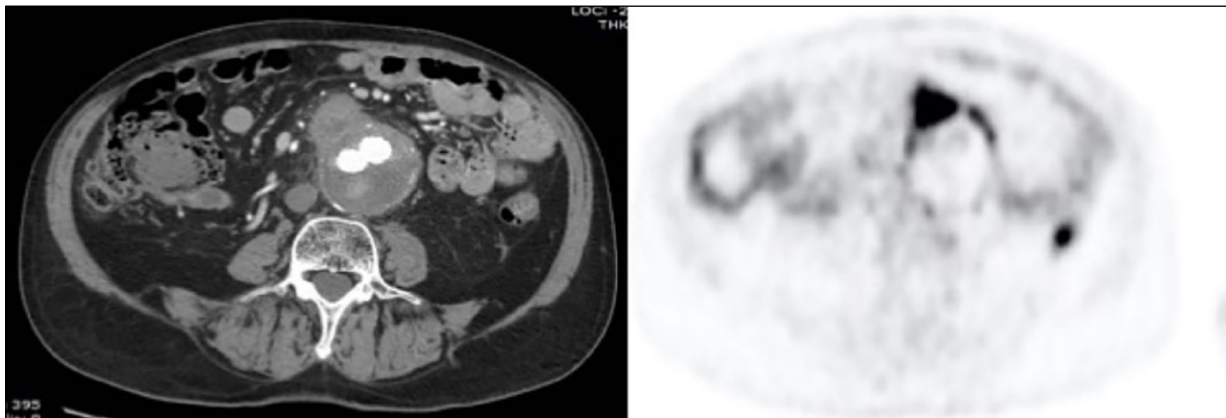


Figure 1. Transaxial images of the contrast enhanced CT (left panel) and $[^{18}\text{F}]$ FDG PET/CT (right panel) showing the bulging at the right antero-lateral side of the aortic wall uptake corresponding to an intense area of $[^{18}\text{F}]$ FDG uptake of focal pattern extending to the anterolateral vascular wall where the uptake presented a linear pattern native abdominal aorta.

To this aim a total body positron emission tomography (PET)/CT with $[^{18}\text{F}]$ FDG was performed, showing an intense radiopharmaceutical uptake at the aortic wall bulging suspected for the presence of infection, extending to the endograft where the area of uptake was limited both in extension and intensity (Figure 1, right panel, and Figure 2). Three sets of blood cultures including at least one aerobic and one anaerobic from a peripheral vein were performed⁷. Cultures were positive for *Listeria monocytogenes*.

At the end of a multidisciplinary discussion, including also the infectiologist, endograft explantation followed by antimicrobial therapy was planned. The surgical operation consisted in median laparotomy. A careful dissection of the entire abdominal aorta was performed. A large lymph node was found very close to the second and third portions of duodenum and to the aneurysmal sac. No intraoperative evidence of aorto-duodenal fistula, and no macroscopic sign of infection were detected. A temporary suprarenal

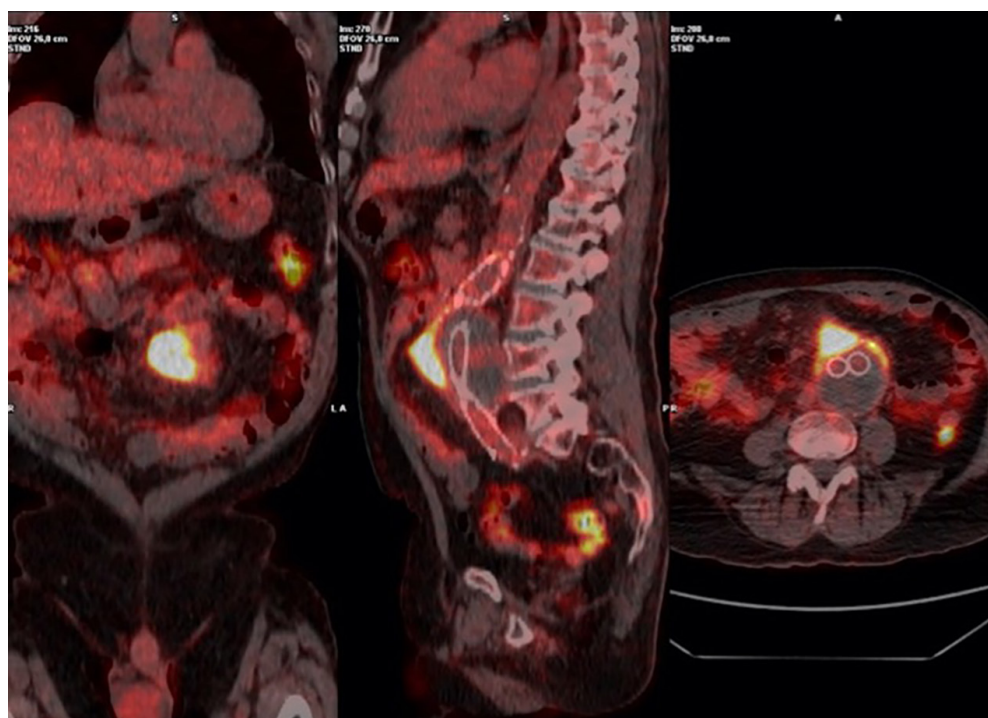


Figure 2. Superimposed $[^{18}\text{F}]$ FDG PET/CT images in the coronal, sagittal and transaxial view (left to right, respectively) better characterizing the extension and the intensity of the radiopharmaceutical uptake at the antero-lateral side of the aortic wall, at the site of the mesenteric enlarged lymph node, and at the anterolateral vascular wall of the native abdominal aorta.

clamping was performed and the endograft was removed. A partial removal of the aortic wall was performed, and a cryopreserved allograft was used to perform the *in-situ* reconstruction with a straight aortic-tube graft (Figure 3). The area was then covered with omentum. Intraoperative cultures were positive for *Listeria* (aortic wall, thrombus, and endograft). The patient had an uneventful hospital stay, and he was discharged on 9th postoperative day.

A long-term antibiotic therapy with endovenous administration of ampicillin-sulbactam, and gentamicin was initiated. One month after surgery, blood tests revealed a complete remission of C-reactive protein and Duplex scan detected the patency of the cryopreserved allograft with absence of defects at anastomotic sites.

Discussion

Listeria monocytogenes is a facultatively anaerobic, intracellular Gram-positive bacillus, that could be found in the soil, and stools of mammals. It could be ingested with contaminated

food (e.g., cheese, poultry, row meat), and water. Pathogens usually spread from the bowel to the bloodstream with the possibility of adherence to the aortic wall and then to the periaortic tissues⁸.

In presence of intravascular grafts, *Listeria monocytogenes* could cause an endograft infection with a mortality rate ranging from 25 to 100% in case of aortic graft infection⁹. However, *Listeria* is not the most common bacterium isolated in infectious diseases of the aorta. In fact, *Staphylococci* and *Salmonella* spp. account for approximately 50-60% and 30-40%, respectively, in case of native aortic infection, whilst *Staphylococci*, *E.coli*, and *Pseudomonas aeruginosa* are more diffuse in case of endograft infections³.

In literature, the reports about endograft infection due to *Listeria monocytogenes* are anecdotal. Heikkinen et al⁵ reported a prosthetic graft infection due to *Listeria monocytogenes* in a 77-year-old man who underwent endoluminal stent grafting for infrarenal abdominal aortic aneurysm. Ma et al¹⁰ described a psoas abscess associated with aortic endograft infection in a 66-year-old man. Shoai-Tehrani et al¹¹ reported the largest study including 71 consecutive cases

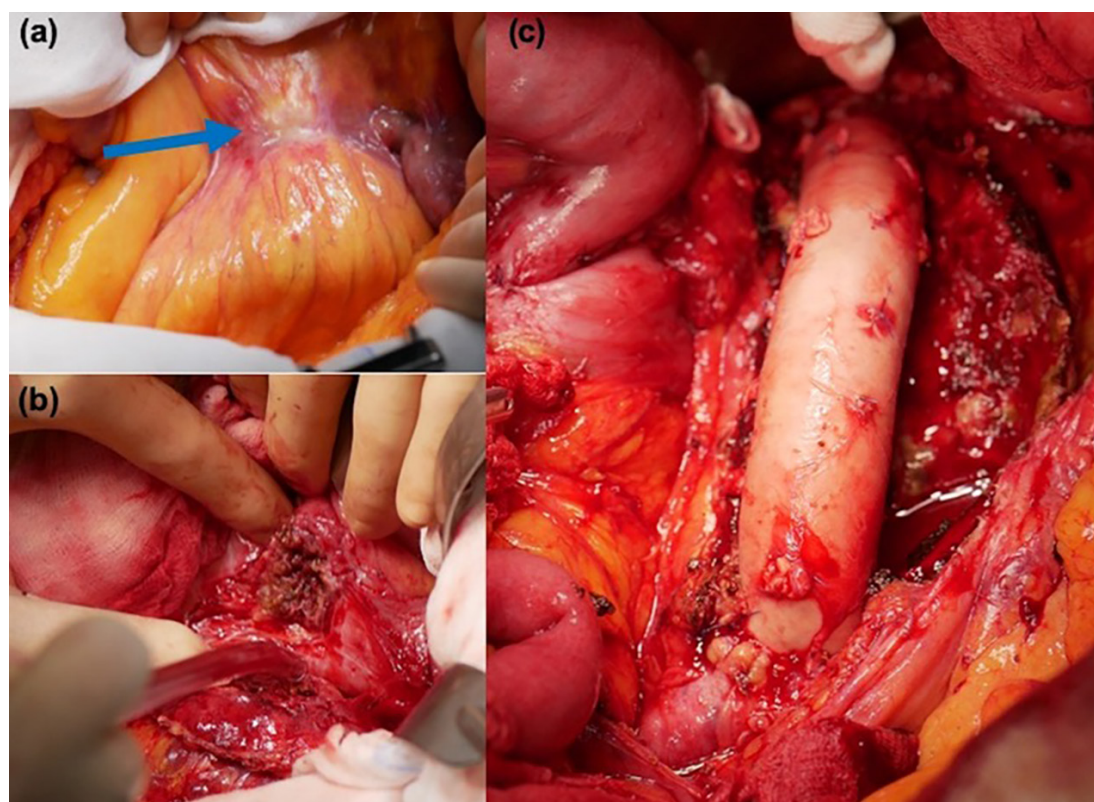


Figure 3. Intraoperative findings: (a) lymph node close to duodenum and aneurysmal sac (blue arrow); (b) surgical dissection of the aneurysmal sac with no aortoduodenal fistula; (c) *in-situ* aortic reconstruction with cryopreserved allograft.

of *Listeria monocytogenes*-associated endovascular infections; however, only 14 patients had prosthetic graft infections (femoro-popliteal, ascendant and descendant aorta) during a 25-years period.

In our case report the endovascular device has been placed into the abdominal aorta 3 years before the clinical onset of infection. Imaging suggested an aortic pseudoaneurysm, because of the integrity of the vessel guaranteed by the adventitia and the surrounding tissues. However, pseudoaneurysms of the abdominal aorta are rarer than endograft infections, accounting for 1% of all abdominal aneurysm¹². PET/CT was essential to obtain an adequate diagnosis of endograft infection whereas blood cultures revealed the type of pathogen.

Histology of aortic wall, removed endograft, and endoaneurysmatic thrombus confirmed the diagnosis of *Listeria monocytogenes* infection. Intraoperatively, the aortic bulging, firstly diagnosed as pseudoaneurysm, was recognized as an enlarged mesenteric lymph node.

In our experience the use of a cryopreserved graft allows us to perform an *in-situ* reconstruction without the need of explantation, ligation of the aortic stump, and non-anatomical revascularization of the lower limbs¹³.

Some aspects of the infection pathogenesis remain unclear. In immunocompromised patients, *Listeria monocytogenes* usually results in a prolonged low-level bacteriemia leading to invasion of secondary organs from bowel^{14,15}. In immunocompetent patients, *Listeria* survives and replicates inside the macrophages. Our hypothesis is that in our case infection originated from the mesenteric lymph nodes with a secondary spread to the aortic wall, and then to the endograft.

Conclusions

Endovascular infections caused by *Listeria monocytogenes* are extremely rare, in particular those involving abdominal endograft. In our case the multidisciplinary approach was crucial; in fact, the differential diagnosis between pseudoaneurysm and endograft infection was obtained throughout the combination of [¹⁸F]FDG PET/CT as second-level imaging test with blood cultures findings. Finally, *in-situ* reconstruction with a cryopreserved allograft followed by prolonged antimicrobial therapy allowed an adequate infection control.

Conflict of Interest

The Authors declare that they have no conflict of interests.

Authors' Contribution

Raffaella Berchiolli, writing, final revision, final approval. Giulia Bertagna, writing, final revision, final approval. Paola Erba, writing, final revision, final approval. Mauro Ferrari, final revision, final approval. Nicola Troisi, writing, final revision, final approval. All authors read and approved the final version of the manuscript.

References

- 1) Rouquette C, Berche P. The pathogenesis of infection by *Listeria monocytogenes*. *Microbiologia* 1996; 12: 245-258.
- 2) Zolin A, Amato E, D'Auria M, Gori M, Huedo P, Bossi A, Pontello M. Estimating the real incidence of invasive listeriosis through an integrated surveillance model in use in Lombardy (Italy, 2006-2014). *Epidemiol Infect* 2017; 145: 2072-2080.
- 3) Swain TW, Calligaro KD, Dougherty MD. Management of infected aortic prosthetic grafts. *Vasc Endovascular Surg* 2004; 38: 75-82.
- 4) Ducasse E, Calisti A, Speziale F, Rizzo L, Misuraca M, Fiorani P. Aortoiliac stent graft infection: Current problems and management. *Ann Vasc Surg* 2004; 18: 521-526.
- 5) Heikkinen L, Valtonen M, Lepantalo M, Saimanen E, Jarvinen A. Infraarenal endoluminal bifurcated stent graft infected with *Listeria monocytogenes*. *J Vasc Surg* 1999; 29: 554-556.
- 6) Alves C, Mendes D, Marques FB. Fluoroquinolones and the risk of tendon injury: a systematic review and meta-analysis. *Eur J Clin Pharmacol* 2019; 75: 1431-1443.
- 7) Raoult D, Casalta JP, Richet H, Khan M, Bernit E, Rovey C, Branger S, Gouriet F, Imbert G, Bothello E, Collart F, Habib G. Contribution of systematic serological testing in diagnosis of infective endocarditis. *J Clin Microbiol* 2005; 43: 5238-5242.
- 8) Masuda S, Takeuchi N, Takada M, Fujita K, Nishibori Y, Maruyama T. Ruptured thoracic aortic aneurysm infected with *Listeria monocytogenes*: a case report and a review of Literature. *Open J Cardiovasc Surg* 2013; 6: 1-7.
- 9) Foulex A, Coen M, Cherkaoui A, Lazarevic V, Gaïa N, Leo S, Girard M, Mugnai D, Schrenzel J. *Listeria monocytogenes* infectious periaortitis: A case report from the infectious disease standpoint. *BMC Infect Dis* 2019; 19: 326.
- 10) Ma JW, Hu SY, Lin TC, Tsai CA. Psoas abscess associated with aortic endograft infection caused by bacteremia of *Listeria monocytogenes*: A case

- report and literature review (CARE Complaint). *Medicine (Baltimore)* 2019; 98: e17885.
- 11) Shoai-Tehrani M, Pilmis B, Maury MM, Robineau O, Disson O, Jouvion G, Couplier G, Thouvenot P, Bracq-Dieye H, Valès G, Leclercq A, Lecuit M, Charlier C. *Listeria monocytogenes*-associated endovascular infections: A study of 71 consecutive cases. *J Infect* 2019; 79: 322-331.
 - 12) Potts RG, Alguire PC. Pseudoaneurysm of the abdominal aorta: A case report and review of the literature. *Am J Med Sci* 1991; 301: 265-268.
 - 13) Janko MR, Bose S, Lawrence PF. Current status of treatment for aortic graft infection: When should cryopreserved allografts be used? *Semin Vasc Surg* 2019; 32: 81-87.
 - 14) Vázquez-Boland JA, Kuhn M, Berche P, Chakraborty T, Domínguez-Bernal G, Goebel W, González-Zorn B, Wehland J, Kreft J. *Listeria* pathogenesis and molecular virulence determinants. *Clin Microbiol Rev* 2001; 4: 584-640.
 - 15) Lepe JA. Current aspects of listeriosis. *Med Clin (Barc)* 2020; 54: 453-458.