

We are IntechOpen, the world's leading publisher of Open Access books Built by scientists, for scientists

5,100

Open access books available

126,000

International authors and editors

145M

Downloads

Our authors are among the

154

Countries delivered to

TOP 1%

most cited scientists

12.2%

Contributors from top 500 universities



WEB OF SCIENCE™

Selection of our books indexed in the Book Citation Index
in Web of Science™ Core Collection (BKCI)

Interested in publishing with us?
Contact book.department@intechopen.com

Numbers displayed above are based on latest data collected.
For more information visit www.intechopen.com



Mechanical Complications of Myocardial Infarction

Serena Mariani, Francesco Formica and Giovanni Paolini

Additional information is available at the end of the chapter

<http://dx.doi.org/10.5772/61373>

Abstract

Complications of acute myocardial infarction are different and life threatening. Prompt diagnosis and therapy are essential. In this, chapter we will analyse mechanical complications, such as ventricular free wall rupture, ventricular septal defect, papillary muscle rupture, ischaemic mitral regurgitation, left ventricle aneurysm, and cardiogenic shock.

Keywords: Mechanical complications, ventricular free wall rupture, ventricular septal defect, papillary muscle rupture, ischaemic mitral regurgitation, left ventricle aneurysm, cardiogenic shock, remodelling

1. Introduction

Complications of acute myocardial infarction are different and sometimes life threatening.

We can globally classify them in five categories: (1) ischaemic complications, which include infarct extension, recurrent infarction, and post infarction angina; (2) arrhythmic complications, in terms of atrial or ventricular arrhythmias, and sinus or atrioventricular node dysfunction; (3) embolic complications towards central nervous system or peripheral embolization; (4) inflammatory disturbances, such as pericarditis; (5) mechanical complications, as myocardial rupture, mitral valve dysfunction, ventricular aneurysms and cardiogenic shock up to heart failure.

Since the last years of the eighteenth century, many physicians discovered these clinical entities, firstly during autopsy, and progressively by doing pioneristic surgical efforts, starting by suturing heart wounds, and gradually trying to apply similar techniques on the infarcted heart.

Mechanical complications of myocardial infarction are direct consequences of anatomopathological changes occurring in ischaemic cardiac tissue. After a coronary occlusion, there is a lack

in perfusion and in oxygen supply that cause functional, morphological, and biochemical alterations. In the first 30 minutes from the occlusion, reversible changes happen; macroscopically and microscopically there are no grossly damages yet, but myofibrils start to relax, and cells start to suffer. After half an hour, ischaemic necrosis begins, and the irreversible damage occurs. Complete necrosis of myocardial cells requires at least 2–4 hours, or longer, depending on the presence of collateral circulation, persistent or intermittent coronary arterial occlusion, pre-conditioning, and individual demand for oxygen and nutrients. The principal mechanism is coagulative necrosis, with neutrophil infiltration, oedema, and loss of myofibrils. After 6–12 hours, loss of vitality is complete. In one week, macrophagic phagocytosis and collagen disruption begin, and tissue becomes weaker; that is the most dangerous step in which heart ruptures are more frequent [1, 2, 3].

The irreversible damage starts at a subendocardic level, and when the ischemia is widespread, necrosis moves forward, involving the adjacent tissue both in width and in thickness. If coronary flow is promptly restored while the damage is still reversible yet, the cells' vitality could be preserved. On the other hand, reperfusion damage could be present by generating free oxygen radicals and apoptosis activators.

After a couple of weeks, granulation tissue and neoangiogenesis begin, up to the formation of a scar in about two months from myocardial infarction. Remodelling of myocardial tissue is the final step; both infarcted and non-infarcted regions change in dimensions, thickness, and shape, with hypertrophy and dilatation of the myocardial wall, and with the possible formation of an aneurysm. Remodelling could be seen as a sort of haemodynamic compensation; nevertheless, degenerative changes in myocardial tissue may cause a depression in regional and global contractility, with a final lack in myocardial function [1, 2, 3].

As we will discuss, on a clinical level, signs and symptoms of mechanical complications of myocardial infarction may vary according to the seriousness of the damage, going from rare asymptomatic medical cases, through plainly symptomatic patients showing classical chest pain, up to more frequent catastrophic, and even sudden onset with cardiogenic shock. Because of these, a prompt diagnosis is important. While ECG may demonstrate the presence of an infarction and help locate the ischaemic lesion, transthoracic echocardiography with Doppler is the modality of choice for bedside diagnosis, capable of detecting heart ruptures, as well as valve defects or ventricular motion abnormalities. Its immediate availability and the detailed information it provides are fundamental in the management of these patients, helping in the decision-making process. The use of other diagnostic tools, such as angiography, is subdued to haemodynamic stability of the patient [3].

As far as therapy is concerned, most of all mechanical complications of myocardial infarction require an urgent surgical approach. Meanwhile, initial management with medical therapy should be administered immediately, in order to improve systemic and coronary perfusion, and stabilise the haemodynamic status. Supplement oxygen and mechanical ventilatory support while necessary should be provided, as well as analgesic therapy, in order to control pain and reduce sympathetic tone; crystalloid infusion should be administered when hypotension and relative hypovolemia is present, together with inotropic agents. Many more pharmacologic agents are useful, depending on every different clinical presentation, but the positioning of an intra-aortic-balloon pump (IABP) is always a support of choice in order to

reduce cardiac workload and increase supply of oxygen by increasing coronary perfusion during diastole and reducing the after-load during systole [4].

Survival depends primarily upon the rapid recognition of each complication and upon an immediate therapy. Even if operative mortality remains high, surgery is the essential tool to avoid a fatal outcome.

In this chapter, we will analyse mechanical complications of myocardial infarction, such as ventricular free wall rupture, ventricular septal defect, papillary muscle rupture, ischaemic mitral regurgitation, left ventricle aneurysm, and cardiogenic shock. We will also deal with therapies for heart failure, and make a brief digression upon strategies against myocardial remodelling.

2. Left ventricular free wall rupture

The first description of left ventricular free wall rupture appeared in 1647 by William Harvey, but until 1970, with operations managed by the teams of Hatcher and FitzGibbon, no successful surgery was done [5, 6].

Left ventricular free wall rupture (LVFWR) is the most frequent presentation of myocardial rupture: it occurs up to ten times more frequently than septal or papillary muscle rupture, and mostly hits the lateral midventricular wall along the apex to base axis (the incidence of right ventricular free wall rupture is very low, roughly 0.44%). Free wall rupture may occur at any time after myocardial infarction, most frequently after 3–7 days, when coagulative necrosis, neutrophil infiltration, and tissue lysis make myocardium weaker. Moreover, an increase in wall tension may overcome the tensile strength of the weakened wall. However, at least 1/4 of heart rupture occurs within the first 24 hours. Interstitial oedema, damage to collagen network and myocyte apoptosis are proposed mechanisms [7].

The real incidence of this complication is unknown, although the reported incidence is increasing (1–4%) among patients surviving hospital admissions due to an increment of the availability of non-invasive diagnostic tools. Free wall rupture accounts for 6–17% of in-hospital mortality [8]. The National Registry of Myocardial Infarction (NRM) shows an elevated incidence of in-hospital mortality among patients treated with thrombolytic therapy (12.1%) than patients who were not treated (6.1%) [9]. In the Thrombolysis in Myocardial Infarction Phase II (TIMI II) trial, 16% of patients died within 18 hours of therapy. Moreover, patients who were treated with PTCA had an incidence of free wall rupture lower than that of patients receiving thrombolytic therapy [10].

Risk factors are age (usually over 60 years old), gender (female), a history of hypertension, and the absence of ventricular hypertrophy. Moreover, LVFWR occurs mostly after an ST elevation myocardial infarction (STEMI), and in areas lacking of fibrosis (that means in patients without history of previous angina or myocardial infarction). These last associations suggest that the size of necrosis and the absence of collateral blood flow (with lack of previous ischaemic symptoms) are important determinants in the aetiology of heart rupture [8].

To understand the clinical presentation of the LVFWR, it is worthy to speak about the morphological pattern of rupture. Pathologically, Perdigo and associates described four types

of ruptures: the type I, or direct rupture, is a single dissection of the wall in only one direction and without dissection or blood infiltration (Fig. 1); type II is represented by a multiple dissection, with a multicanalicular trajectory and an extensive haemorrhagic infiltration of neighbouring tissue (Fig. 2); in type III, rupture is protected either by an intracardiac thrombus or by adhesions on the epicardial side (Fig. 3); type IV is characterised by an incomplete rupture, that doesn't cross the thickness of the ventricular wall, creating an intramural haematoma [12]. However, Becker and van Mantgem proposed a different classification that could be connected to the clinical presentation: acute, subacute, and chronic [13]. The acute rupture (also called "blow-out" rupture, corresponding to Perdigao type I-II) is characterized by a massive haemopericardium (Fig. 4); the presentation is dramatic, with sudden and recurrent or persistent chest pain and a rapid deterioration into electro-mechanical dissociation caused by pericardial tamponade. A severe jugular venous distention and cyanosis may be present. Death occurs within a few minutes. When the rupture area is smaller, and temporarily sealed by thrombus or pericardial adhesions, a subacute onset happens (also called "ooze" rupture or Perdigao type III, and occurs in 30–40% of cases). Clinical presentation may involve the gradual onset of signs and symptoms of cardiac tamponade. A variety of other signs may be present, such as arrhythmias, a severe hypotension, syncope, and, eventually, cardiogenic shock, but also malaise and nausea for few days.

A chronic rupture occurs when the leakage of blood is slow and when surrounding pressure on the epicardium temporarily controls the haemorrhage, with the formation of a false aneurysm (or pseudoaneurysm). This is a rare entity and usually occurs within three months after myocardial infarction. Clinical presentation, in this case, is represented by congestive heart failure, recurrent or persistent chest pain, ventricular arrhythmias, and even embolization [14].

Perdigao type IV (intramural haematoma) has no different presentation from the usual infarction.

Perdigao	Becker and van Mantgem	
Type I	Acute ("blow-out") rupture	Single dissection of the wall, in only one direction and without dissection or blood infiltration Fig. 1
Type II		Multiple dissection, with a multicanalicular trajectory and an extensive haemorrhagic infiltration of neighbouring tissue Fig. 2
Type III	Subacute ("ooze") rupture	Rupture is protected either by an intracardiac thrombus or by adhesions on the epicardial side Fig. 3
	Chronic rupture (pseudoaneurysm)	Pressure on the epicardium temporarily controls the haemorrhage
Type IV		Intramural haematoma

Table 1. Nema

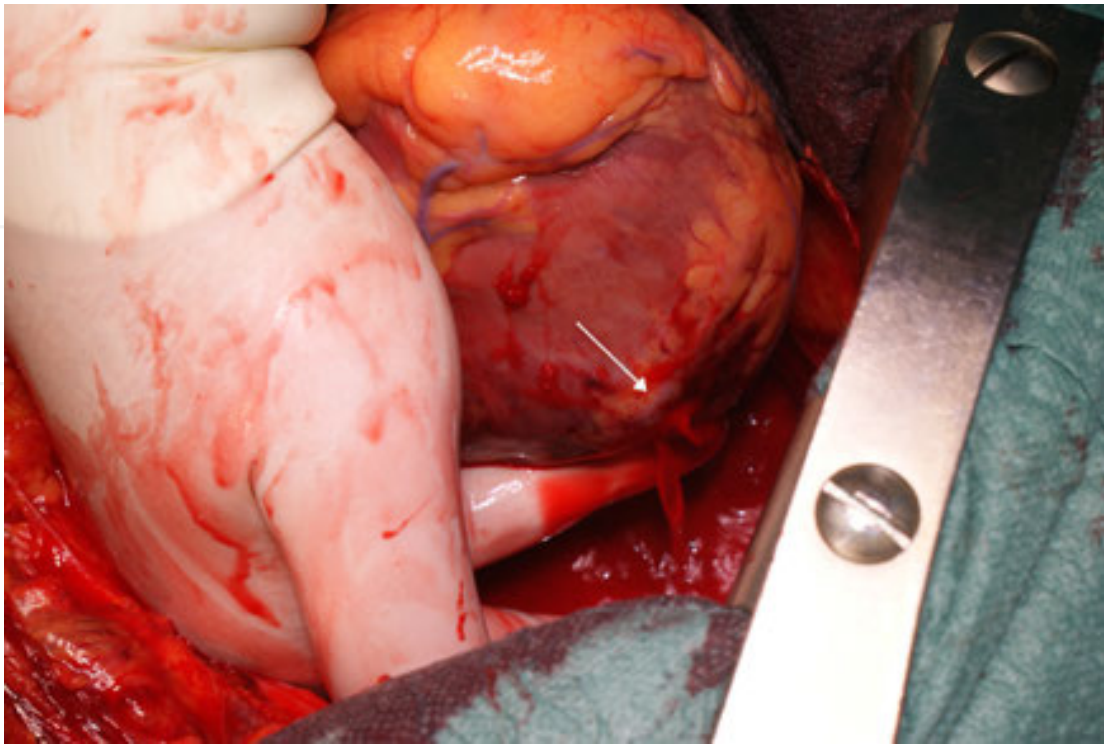


Figure 1. Perdigao type I, a single dissection of ventricular free wall

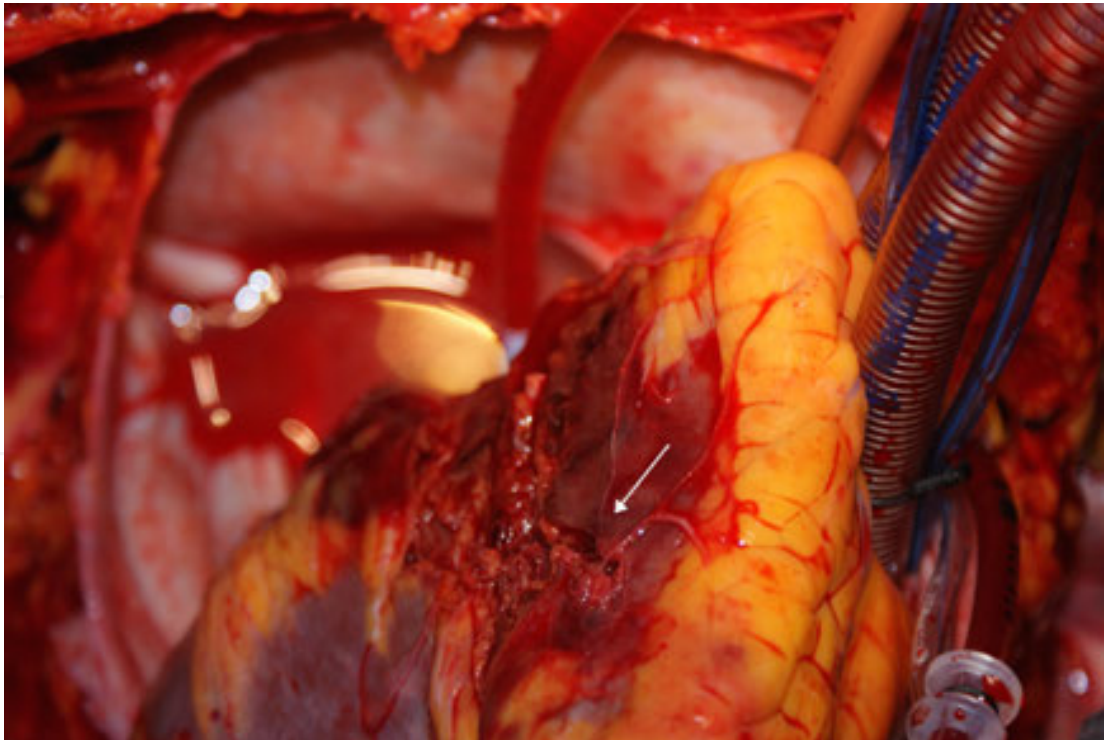


Figure 2. Perdigao type II, multicanalicular trajectory of rupture

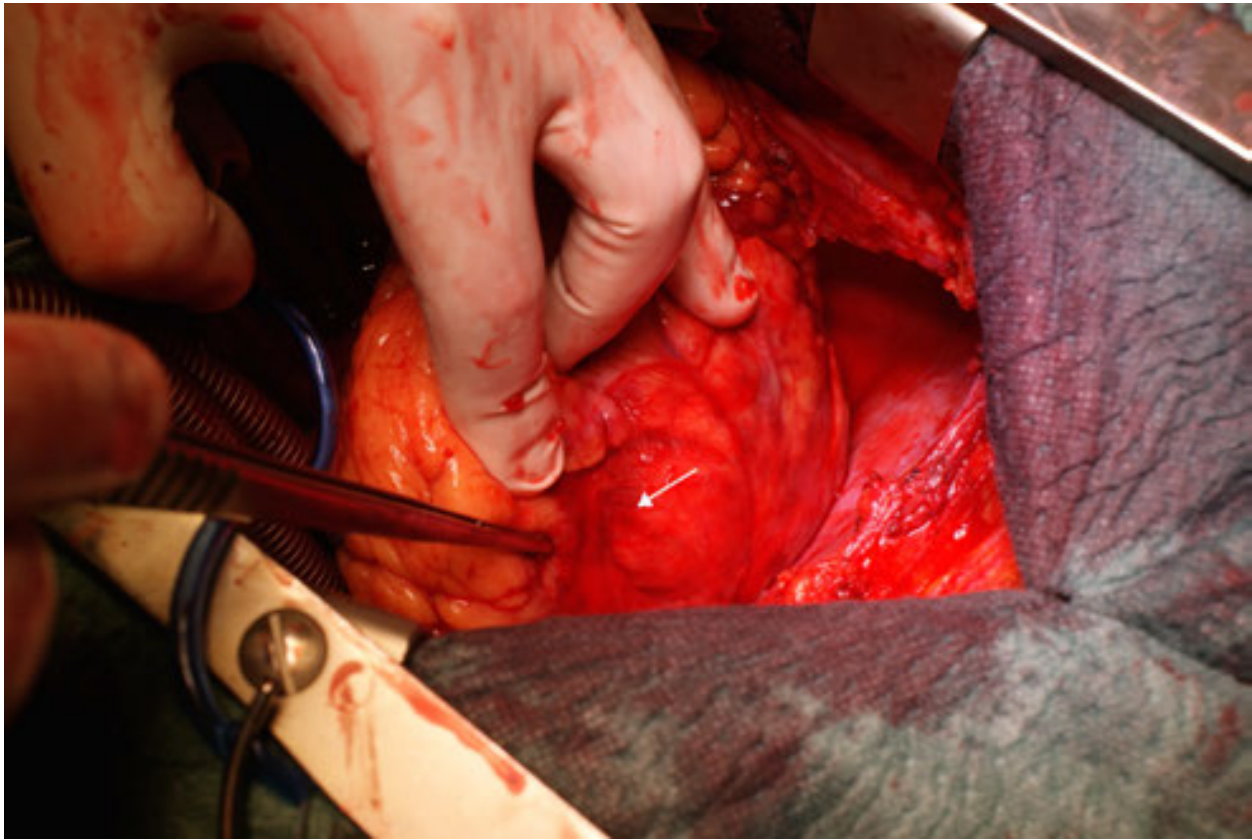


Figure 3. Perdigao type III, rupture is sealed by pericardial adhesions

Early diagnosis is improved by the use of transthoracic echocardiography, the fastest and most useful diagnostic test, with a high diagnostic sensitivity ($\geq 70\%$) and specificity ($> 90\%$). The most frequent finding is the presence of a pericardial effusion (> 5 mm), high-density intrapericardial echoes, right atrial or right ventricular wall compression with tamponade, and, in 50% of cases, visible wall defects [15]. The role of the invasive diagnostic tools is still unclear and depends on the haemodynamic stability of the patient. Most of the time, the definitive diagnosis is made at surgery. Generally, when Perdigao type I, II, III, and IV are non-haemodynamically stable they require a surgical approach. Type IV in haemodynamically stable patients can be treated conservatively [11, 17, 18, 19].

The first objective of treatment is to reach haemodynamic stability. Rapid infusions of crystalloid along with inotropic agents may help to achieve this; pericardiocentesis may be carried out prior to surgery and not only may confirm a haemorrhagic effusion, but also may decrease the threat of tamponade. Placement of IABP should be done [20].

Surgical repair of the rupture site is the definitive treatment, and it can be administered in different ways and with different techniques. Traditional and standard repair involves performing infarctectomy (including the area hit by the rupture) and reconstructing the ventricle or close the damage with simple pledgeted suture (Fig. 5), with or without cardio-

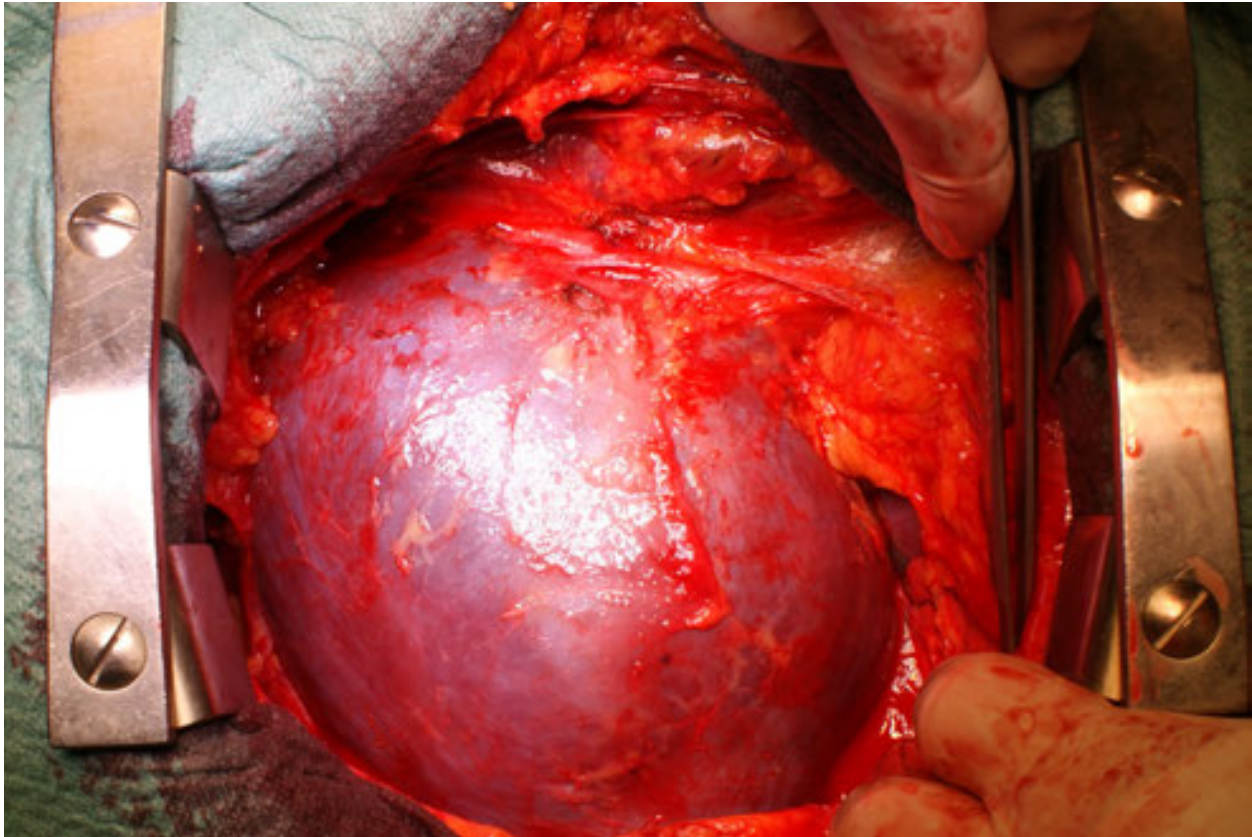


Figure 4. Haemopericardium

pulmonary bypass. Both techniques have a shortcoming: in the first case, a ventricular cavity distortion may damage the ventricular function; on the other hand, stitches are placed in a necrotic—and so weaker—tissue. Different authors have recently reported newer surgical strategies, usually performed in the presence of oozing or sealed rupture (type III), by using different biological materials such as pericardium (Fig. 6) and newer acellular xenogeneic extracellular matrix patches, and non-biological patches made of polyethylene terephthalate polyester fibre (Dacron) or polytetrafluoroethylene fluoropolymer resin (Teflon). Suturless techniques with fibrin tissue-adhesive collagen fleece, and Gelatin-Resorcin Formaldehyde glue are described [12, 16, 21, 22, 23].

In the matter of chronic rupture, the treatment of choice is still surgery, but obviously the timing depends on the balance between risks and benefits. Pseudoaneurysm can be repaired by the closure of the neck or by using a patch (similar to true aneurysm). Percutaneous approaches (by using the Amplatzer™ occluder) are described as well [24].

The mortality rate is significantly high. It is strictly linked to the preoperative haemodynamic condition of patient and to a prompt diagnosis.

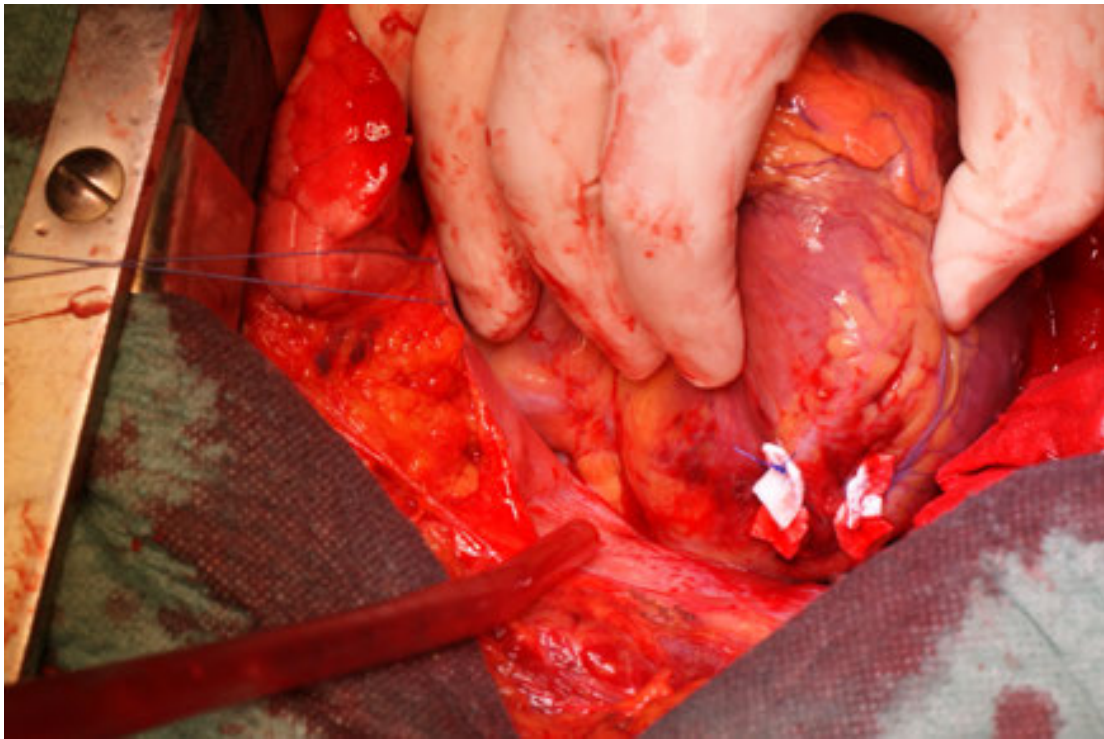


Figure 5. The damage has been closed with simple pledgeted suture

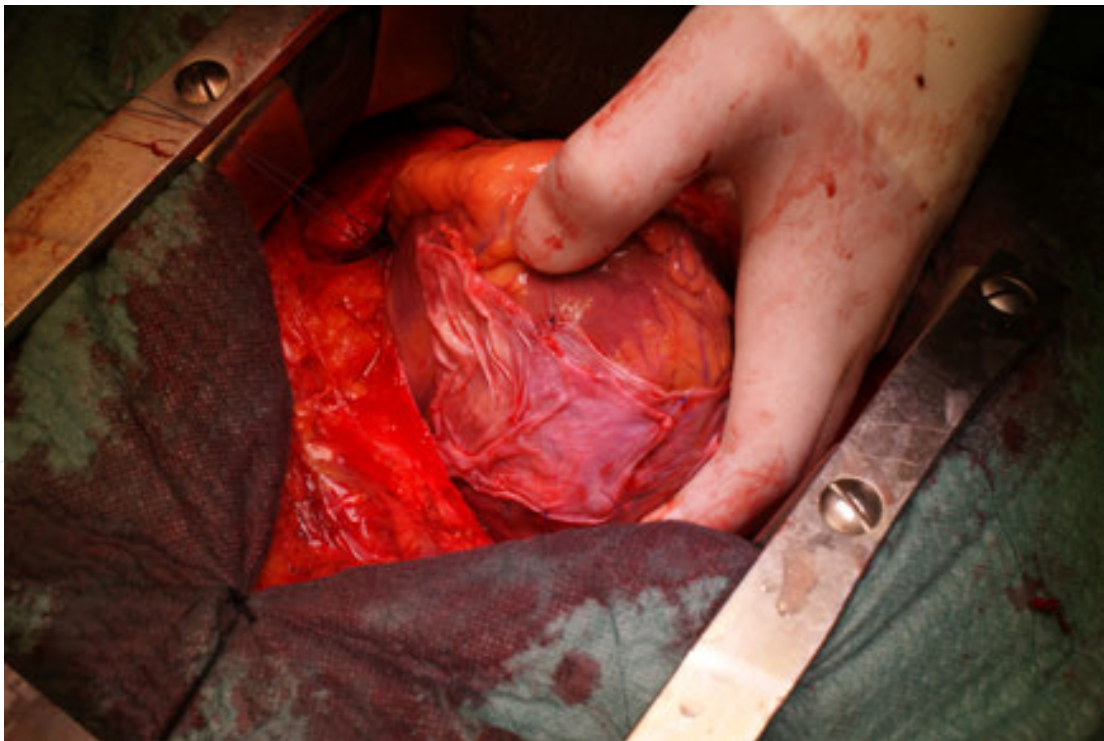


Figure 6. The damage has been sealed by using a pericardial patch

3. Interventricular septal rupture

Ventricular septal defect (VSD), firstly described by Latham in 1845 [25], is a serious complication of myocardial infarction that is little less frequent than free wall rupture. Its incidence has been estimated between 1% and 2% of all myocardial infarctions even if the advent of reperfusion therapy has decreased this value below 0.5%. However, the mortality is still high, with 60–70% of patients dying within the first 2 weeks, and less than 10% survives after 3 months [26].

As for free wall rupture, risk factors for septal rupture include advanced age, hypertension, and no previous myocardial infarction or angina.

The acute rupture occurs 3–7 days after a huge transmural infarction, with the weakening of the septal wall, but the median decrease below 24 h with the use of thrombolysis. Late rupture is possible (as long as 2 weeks). Pathophysiologically, this results in a left-to-right shunt with diversion of blood flow towards pulmonary circulation. Systemic vasoconstriction in response to peripheral hypotension and hypoperfusion worsens the shunt. As a consequence, low cardiac output and cardiogenic shock occur [2].

Classification of the defect are of three types: type I ruptures show an abrupt tear in the wall of normal thickness; in type II, the infarcted myocardium erodes before the rupture, and is covered by thrombus; type III shows perforation of an aneurysm grown after infarct healing. Moreover, defects can be classified in two other categories: simple and complex. Multiple defects may be present in 5–11% of cases, and are probably caused by infarct extension. Simple rupture is a discrete lesion, with holes located at a similar level in both ventricles and in a linear path. This is the typical pattern of an anterior infarction and usually hits the part in which the septum meets the free wall. On the other hand, inferior infarction usually leads to a complex type, which presents a meandering dissection path between ventricles and extensive haemorrhage in the nearby tissue that occurs near the base of the heart. Midseptal defects are rare and are usually elicited from the occlusion of a perforating artery [4].

In both cases, rupture may vary in size from mm to cm. This determines the magnitude of left-to-right shunting, influencing the clinical presentation (from asymptomatic to cardiogenic shock), and the likelihood of survival. Signs and symptoms may include recurrent chest pain and dyspnoea, but even a precipitous onset of haemodynamic compromise characterised by hypotension and biventricular failure (often predominantly right-sided failure), up to cardiogenic shock is possible. At physical examination, a harsh and loud pansystolic murmur at the left lower sternal border is present in over 90% of cases. A palpable thrill can be detected in up to 50% of patients [27].

ECG shows changes associated to myocardial infarction and may help to correlate the localization of infarction with the type of septal rupture.

Historically, the gold standard diagnostic tool was right cardiac catheterization using a Swan-Ganz catheter, useful also to differentiate among other clinical entities (mitral ischaemic regurgitation and papillary muscle rupture). In septal rupture, it is easy to find oxygen saturation step-up between the right atrium and pulmonary artery greater than 9% (in papillary rupture, giant V-waves in pulmonary artery wedge pressure are shown). Nowadays,

the use of echocardiography (both transthoracic and transesophageal) has almost replaced this diagnostic tool. Doppler may easily and accurately identify the location, the size, and the presence of the shunt, indeed, with 100% specificity and 100% sensitivity. It may also assess the ventricles function and estimate the right ventricle systolic pressure. The use of angiography is debatable; it can provide important information about coronary lesions, but, on the other hand, may delay the surgical treatment [28].

Kirklin and colleagues reveal that nearly 25% of patients with post infarction septal rupture and no surgical intervention died within the first 24 hours, 50% died within 1 week, 65% within 2 weeks, 80% within 4 weeks [28]; only 7% lived longer than one year. In the GUSTO-I trial, the 30-day mortality rate was lower in patients treated with surgical repair than in patients treated only medically (47% vs. 94%). The same results for the 1-year mortality rate (53% vs. 97%) [29]. In the SHOCK trial, the in-hospital mortality rate was higher in patients with cardiogenic shock due to septal rupture (87.3%) than in patients with cardiogenic shock from all other causes (59.2% with pure left ventricle failure and 55.1% with acute mitral regurgitation) [30].

The optimal approach varies with the clinical presentation. Medical therapy is considered to be a support tool in the offing of surgery, and is usually managed with the use of pharmacologic support with vasodilators (which reduce afterload, thereby decreasing left ventricular pressure and the left to right shunt), inotropic agents (which may increase the cardiac output), diuretics, and IABP. In patients with cardiogenic shock, death is inevitable in the absence of urgent surgical intervention. Delayed elective surgical repair is feasible in patients with heart failure without shock, but an unpredictable and rapid deterioration is always lurking in general; adverse outcomes are correlated with advanced age and a lengthy delay between septal rupture and operation [28].

The surgical approach has been performed since 1959 when Cooley and associates performed the first successful surgical repair through a right ventriculotomy with incision of right ventricular outflow tract [31]. Disadvantages of this approach were suboptimal exposure and failure to eliminate the bulging segment of infarcted left ventricular wall. Later, Heimbecker [32] and colleagues developed a different technique, performing a left ventriculotomy. Nowadays, multiple techniques are described. Apical amputation is simpler, but apical defects are rare. This technique was proposed in the 1970s by Daggett [33]. After the resection, the ventricular free walls are linked using Teflon strips. Other techniques involve infarct exclusion and defect closure with a patch (biological or synthetic) using both stitches and glues [34].

Preservation of the geometric configuration of the ventricles is an important target, together with the closure of the defect.

Even a percutaneous approach has been considered, mostly in order to close contingent residual defects (residual defects are present in about 28% of survived patients) or sometimes used for the acute stabilization of critically ill patients. However, no long-term outcome data about this mini-invasive technique are available [35].

Despite continuous advances in surgical approaches, operative mortality remains high (20–50%), with no clear differences between different techniques (Fig. 7–13) [34].

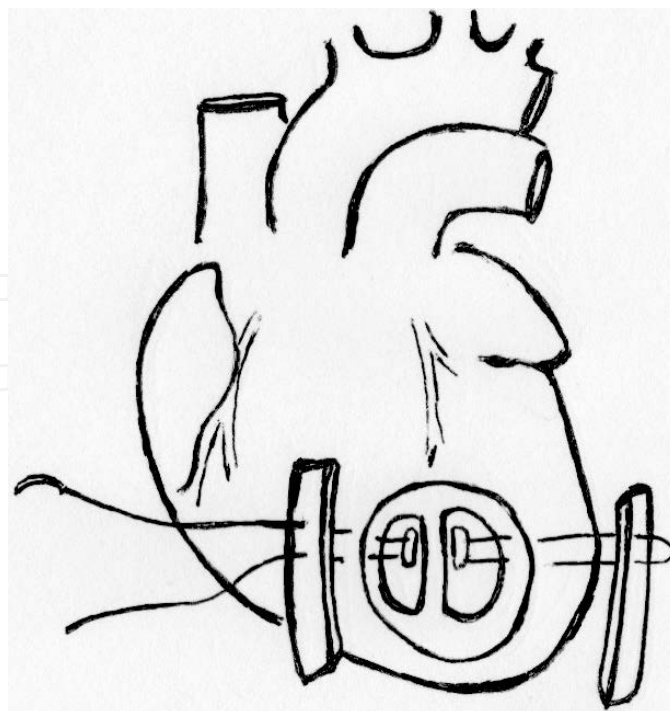


Figure 7. Anterior repair of VSD [Adapted from Chikwe J, Beddow E, Glenville B. Cardiothoracic Surgery. Oxford University Press 2006]

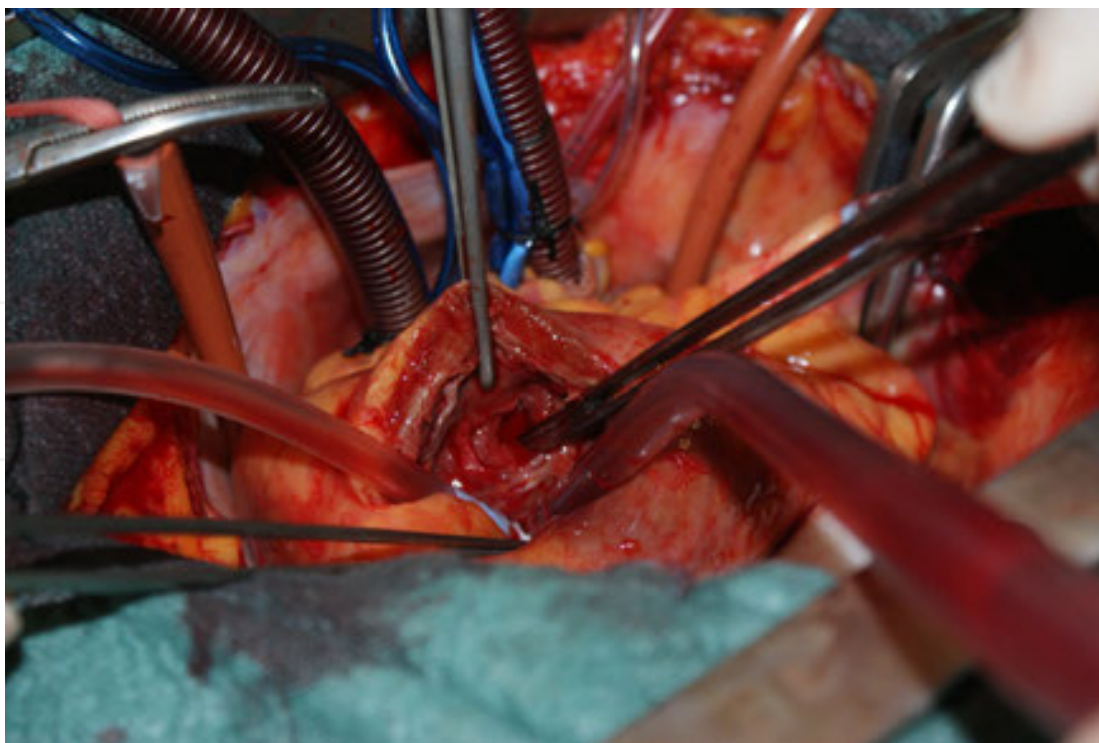


Figure 8. VSD, anterior surgical approach

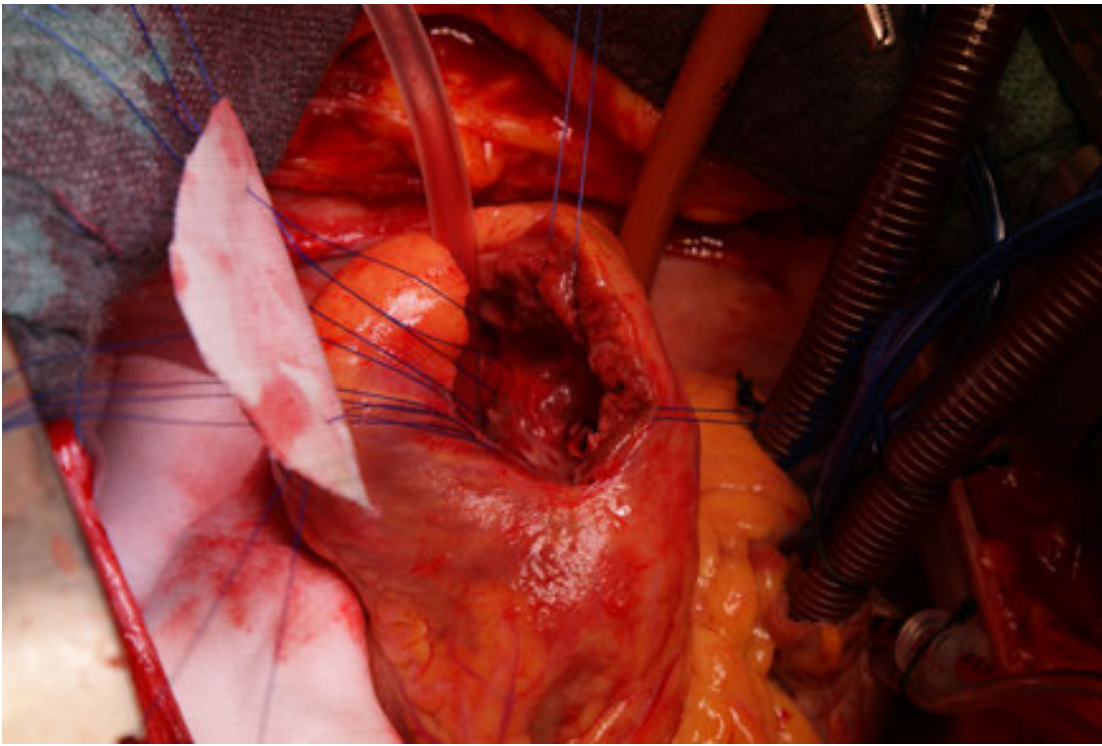


Figure 9. VSD closure with synthetic patch

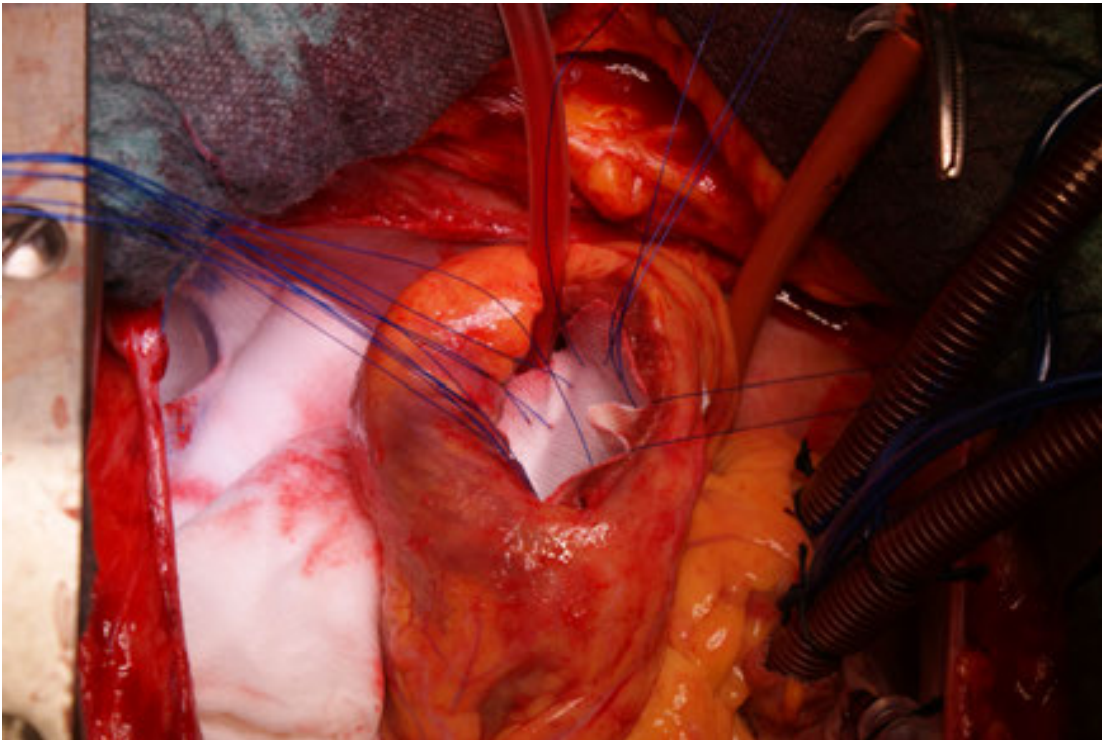


Figure 10. VSD closure with synthetic patch

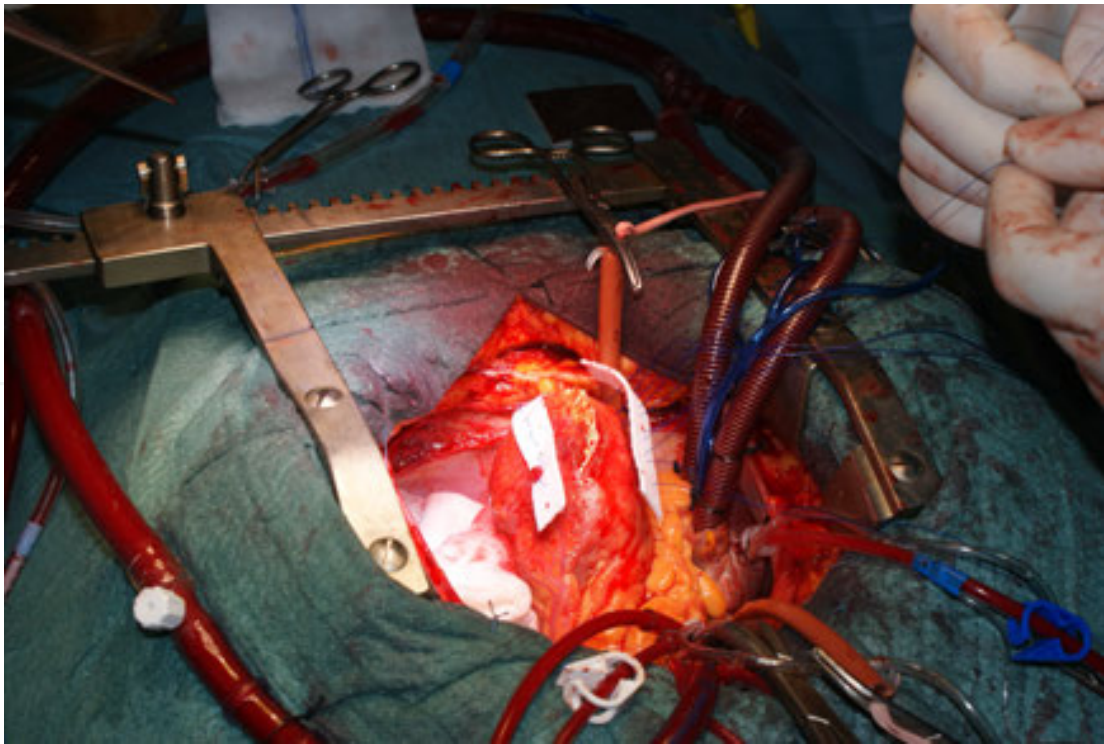


Figure 11. Ventricular free walls are linked using Teflon strips

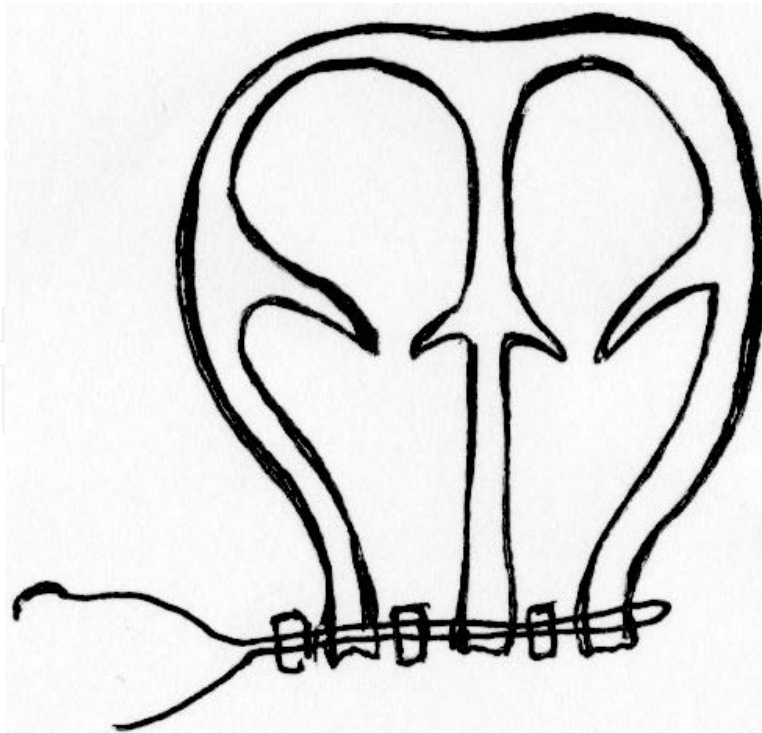


Figure 12. Apical resection [Adapted from Chikwe J, Beddow E, Glenville B. Cardiothoracic Surgery. Oxford University Press 2006]

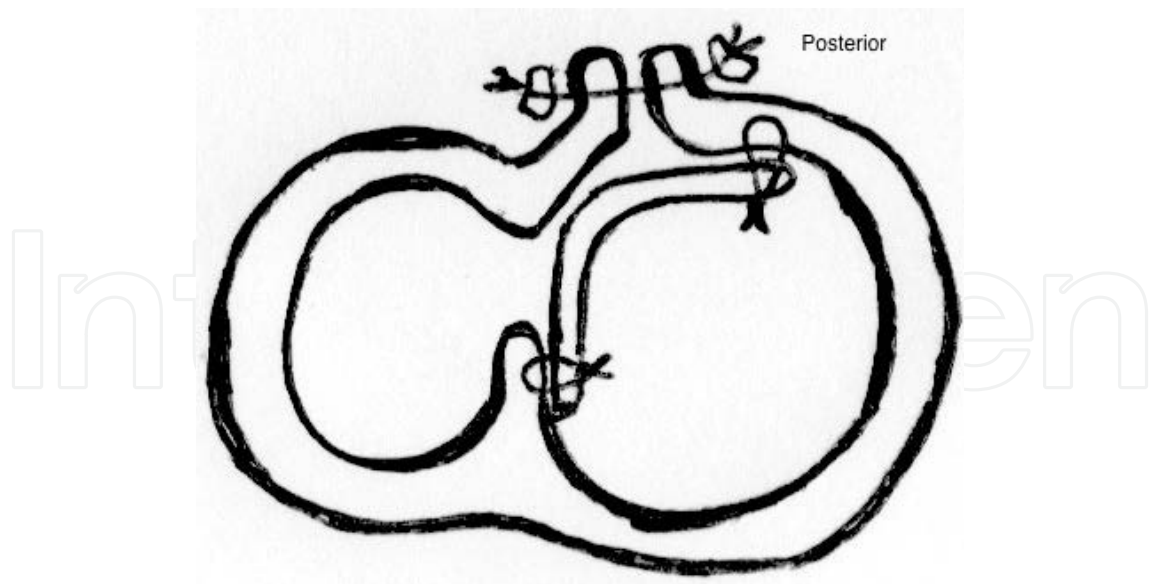


Figure 13. Posterior repair of VSD [Adapted from Chikwe J, Beddow E, Glenville B. *Cardiothoracic Surgery*. Oxford University Press 2006]

4. Papillary muscle rupture

Papillary muscle rupture (PMR) is a rare entity and occurs in about 1% of patients with acute myocardial infarction. It accounts for 5% of infarct-related deaths. Mortality may be as high as 50% in the first 24 h, and up to 80% in the first week, when only medical treatment is applied. Timing of rupture stays in a range between 1 and 14 days, but 80% occurs in 7 days [36].

Rupture of papillary muscles results from infarction of the muscle itself and leads to an ischaemic mitral regurgitation by lack of leaflet tethering (Carpentier type II, see next chapter for further information).

PMR is most common with an inferior myocardial infarction, and the posteromedial papillary muscle is most often involved (6 to 12 times more frequently than anterolateral papillary muscle); that's because of its single blood supply through the posterior descending coronary artery (anterolateral papillary has a dual blood supply, instead, from the left anterior descending and left circumflex arteries) [36, 37, 39].

Among risk factors, there is, once again, the absence of a previous infarction in medical history.

PMR may be complete, with a massive mitral regurgitation and rapid onset of symptoms up to hemodynamic collapse and death, or partial, with a moderate to severe mitral regurgitation. Clinical presentation may vary according to the completeness of rupture, but usually presents dyspnoea, hypotension, acute pulmonary oedema, and cardiogenic shock. At the physical examination, a soft murmur without thrill may be present, even if the absence of new heart murmur does not exclude the diagnosis.

The gold standard in diagnosis is Doppler transthoracic and transesophageal echocardiography, with the evidence of a tear in papillary tissue and the flail of mitral leaflet leading to severe mitral regurgitation (Fig. 14, 15). Left ventricular function is usually hyperdynamic as a result of ventricular contraction against the low impedance left atrium. Haemodynamic monitoring with a Swan-Ganz catheter can reveal large (> 50 mmHg), early V waves in the pulmonary capillary wedge pressure, and no increase in oxygen saturation from right atrium to right ventricle (useful to conduct differential diagnosis with septal rupture) [36, 37, 38].

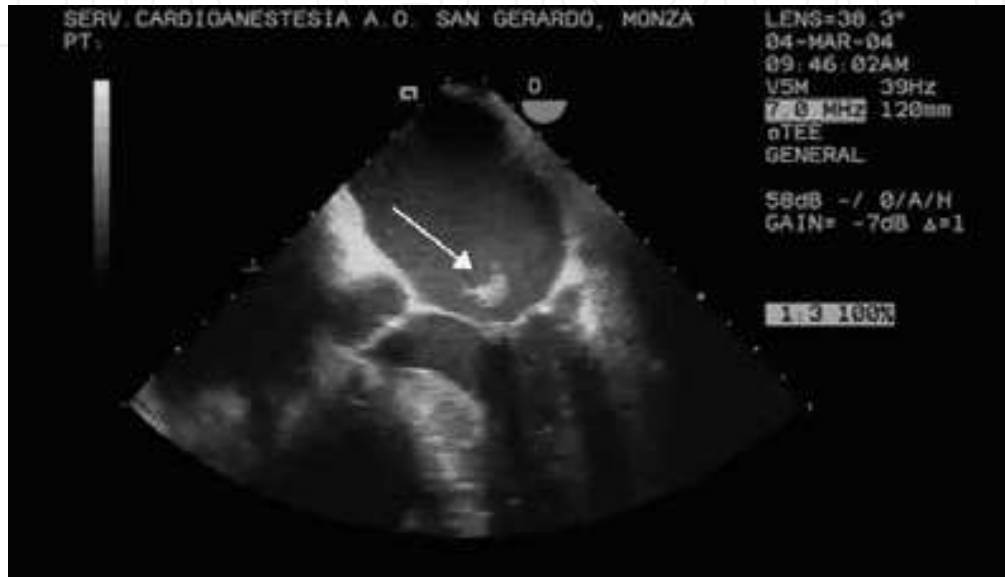

Figure 14. Echo findings in complete papillary muscle rupture

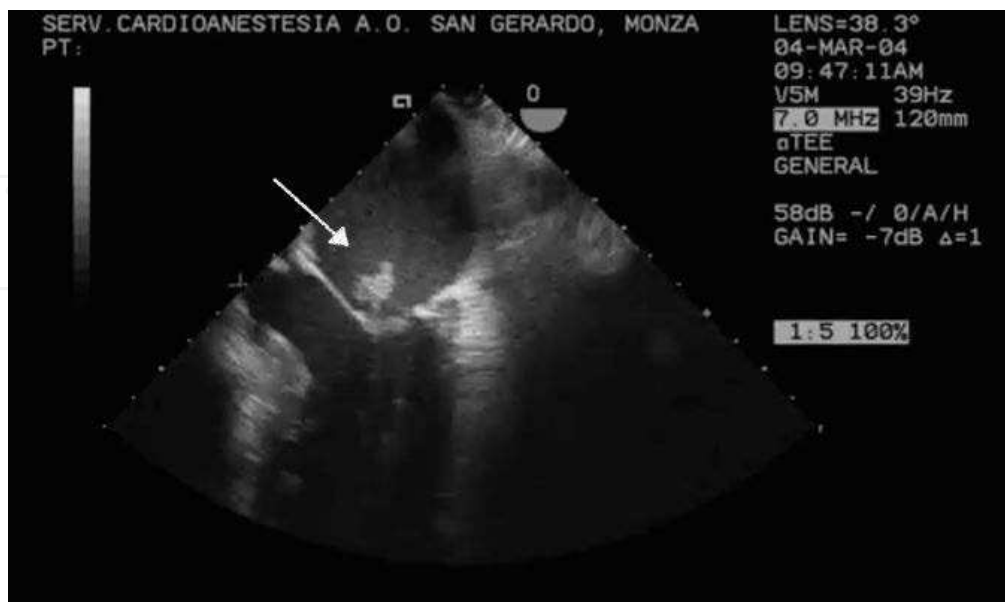

Figure 15. Echo findings in complete papillary muscle rupture

The only real treatment for papillary muscle rupture is surgery, although it is high risk (operative mortality up to 20–25%) [37]. Medical therapy could be performed in order to reach a hemodynamic stability prior to emergency surgery, and includes aggressive afterload reduction in order to decrease the regurgitant fraction by using nitrates, sodium nitroprusside, diuretics, and IABP.

The surgical technique depends upon the location and the completeness of the rupture. With partial PMR, some surgeons prefer to stabilise the patient and delay surgery for 6–8 weeks after myocardial infarction to avoid operating on the necrotic myocardial tissue. However, an acute intervention in patients that cannot be stabilized must be considered. A surgical repair of the papillary muscle head is really rare, but possible, with pledgeted sutures and the addition of glue to strengthen the repair. Mitral valve repair rather than replacement should be attempted when there is no papillary muscle necrosis [36, 37].

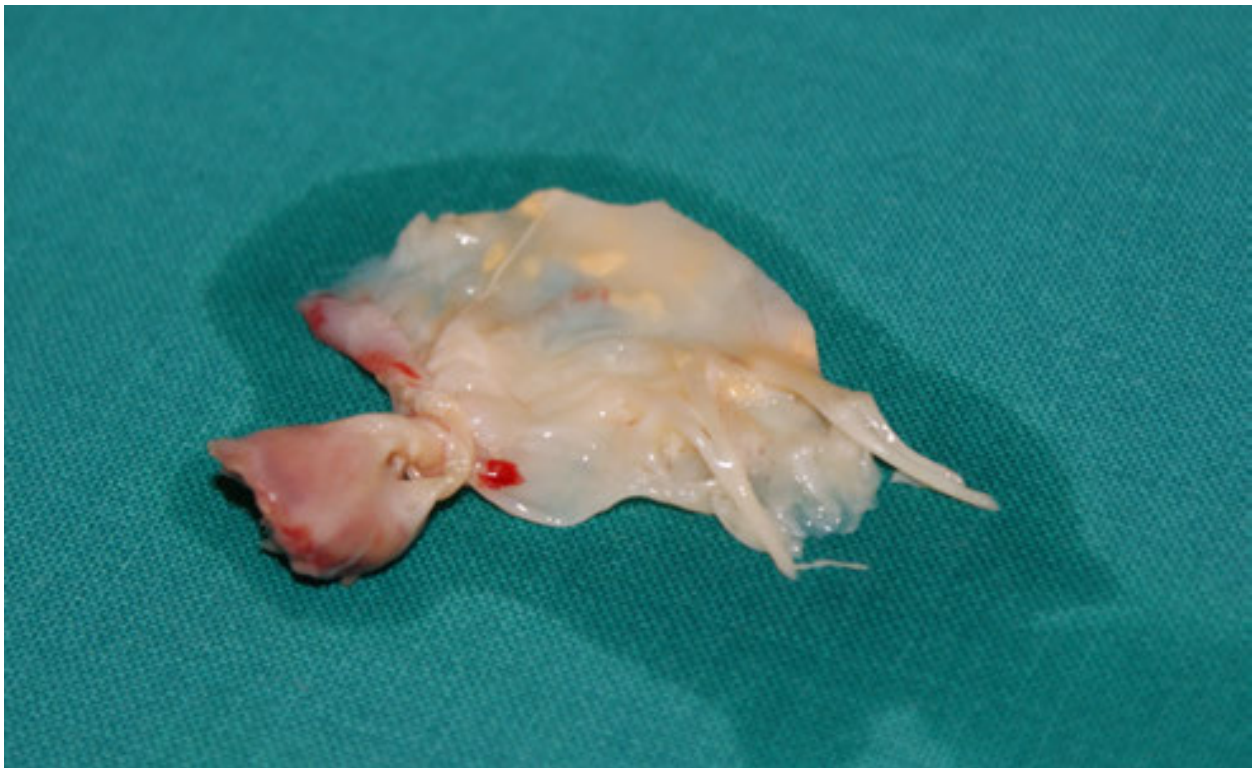

Figure 16. The excised mitral valve showing complete rupture of the papillary muscle

5. Ischaemic mitral regurgitation

Ischaemic mitral regurgitation (IMR) is a functional entity that occurs in 8% to 50% of patients after myocardial infarction. Unlike the structural mitral regurgitation, here the valve leaflets and valvular apparatus are normal, even if the coexistence of coronary artery disease and non-ischaemic mitral disease has led to a poor understanding of this clinical entity [40].

Carpentier described three general types of mitral regurgitation according to different pathophysiologic mechanisms: type I, in which there is a normal leaflet motion, and regurgitation is caused by annular dilatation from ischemia of adjacent ventricular wall or by leaflet perforation; type II, in which we can find an increased leaflet motion, with a prolapse of valve leaflet (in this case, regurgitation is caused either by papillary muscle rupture or in papillary muscle elongation due to chronic ischemia, and usually lead to an asymmetric leak); type IIIa, with leaflet restriction during systole and diastole (not seen in ischaemic mitral regurgitation); type IIIb, leaflet restriction only during systole caused by a dysfunction of ventricular wall, dilated after ischaemic injury, with systolic tethering of papillary muscle (as a consequence, there's a failure in mitral coaptation).

IMR could be acute or chronic, but both result from ischemia of ventricular wall and missed coaptation. The remodelling secondary to acute and chronic ischemia remains the principal mechanism for IMR and depends on apical tethering and an excessive tenting volume, which cause coaptation failure of the mitral leaflets. Mild-to-moderate mitral regurgitation is often clinically silent and detected on Doppler echocardiography performed during the early phase of myocardial infarction.

Risk factors are advanced age, female sex, large infarct, multivessel coronary artery disease, and, unlike other mechanical complications, history of a previous myocardial infarction or recurrent ischemia.

The acute onset of severe IMR is a life-threatening complication and arises from a few hours to weeks after myocardial infarction; in this case, a sudden volume overload is imposed on the left ventricle, increasing preload and a small increase in total stroke volume. Acute mitral regurgitation usually results from the rupture of papillary muscles or chordae tendineae: haemodynamic deterioration is sudden, because no compensatory structural changes in atrium and ventricle are possible. Pulmonary congestion, as well as cardiogenic shock, may occur. Clinical features include pulmonary oedema, chest pain, and dyspnoea. A new pansystolic murmur can be detected, best heard at the apex [40, 44].

Chronic IMR occurs as a consequence of ventricular dilatation secondary to ischaemic ventricular remodelling (both regional or global), with papillary muscle displacement and failure of leaflet coaptation. During chronic onset of the disease, the left atrium and ventricle may develop an offsetting hypertrophy and dilatation. Enlargement of the left atrium allows volume overload, but may cause arrhythmias, such as atrial fibrillation, and the formation of thrombi. Until systolic dysfunction prevents effective ventricular contraction, patients are asymptomatic. After that, exertional dyspnoea and fluid retention may be present [40].

The gold standard diagnostic tool is echocardiography, both transthoracic and transeoesophageal, which assess mitral valve apparatus, the mechanism of regurgitation, and the ventricular function [3, 15]

Medical therapy may have a supportive role in case of acute onset of mitral regurgitation, while in chronic cases it is useful in decreasing the regurgitant volume and improve ventricular function by using ACE-inhibitors, and to reduce remodelling by using beta-blockers. Most patients with acute mitral regurgitation are managed with percutaneous coronary intervention

(PCI) or thrombolysis. Surgery is usually reserved for acute and severe cases, which do not ameliorate after these approaches, and for chronic patients symptomatic for coronary disease.

Repair versus replacement of the mitral valve is still debatable. Mitral valve repair is generally preferred whenever possible based on valve pathology and patient stability: it avoids long-term anticoagulation, decreases infective endocarditis risk, and provides greater leaflet durability. Among repairs, different techniques are available, but annuloplasty with prosthetic ring is the gold standard [41, 42]. On the other hand, valve replacement is usually reserved for situations where the valve cannot be reasonably repaired, or when repair is unlikely to be tolerated clinically. Moreover, it being a faster procedure is better in high-risk surgical candidates. Mitral valve replacement could be managed by using the chordal-sparing techniques, a range of procedures that permit the resuspension of chordae and the preservation of subvalvular anatomy [43].

Percutaneous approaches are available, but often limited to patients with lots of comorbidity and a poor surgical outcome [40].

6. Left ventricular true aneurysm

The earliest reports of a ventricular aneurysm appeared in 1757, during an autopsy managed by Galeati and Hunter; but the first surgical approach to this pathology was performed in 1942 by Beck.

A true aneurysm is the result of the gradual thinning and the expansion of the scarred left ventricular wall after transmural infarction. This is a different entity from a pseudoaneurysm, which does not contain all the three layers of the myocardium and is frequently lined by pericardium and mural thrombus [45, 47, 49].

The 85% of true aneurysm is located anterolaterally, near the apex of the heart. Two types of true aneurysm are present: a traditional aneurysm, namely a region of myocardium with an abnormal diastolic contour and a systolic dyskinesia, with a paradoxical bulging; and a functional aneurysm, in which bulging is not present, but is characterised by large areas of akinesia, that affects ventricular function. They originate from two distinct phases of myocardial infarction. First, an early expansion phase defined as the deformation or stretch of infarcted myocardium during the first week after the ischaemic injury: wall thinning due to the degradation of collagen matrix and dilatation lead to an augmentation in both systolic and diastolic wall stress, following LaPlace law, and to a greater request of oxygen supply. Fibre stretching is progressive until fibrosis and scarring. Increased diastolic stretch, elevated catecholamines and stimulation of natriuretic peptides may demonstrate increased fibre shortening and myocardial hypertrophy as adaptive changes. The second phase is constituted by late remodelling. Here, the aneurysm is composed of scar tissue; systolic and diastolic ventricular dysfunctions are present, in fact aneurysm does not contract nor distend (this impairs diastolic filling and increases left ventricular end-diastolic pressure). Mechanism of compensation such as chamber dilatation, hypertrophy, and changes in ventricular geometry lead to a poor contractile function, and eventually heart failure [46, 48]

The incidence of true aneurysm is 10–35% after transmural myocardial infarction, even if it may result from trauma, Chagas' disease, sarcoidosis, or may be congenital as well. Risk factors seem to be the presence of a previous infarction in medical history and a decreased ejection fraction (less than 50%).

Clinical presentation often involves angina (in more than 60% of patients, three-vessels coronary disease is present), dyspnoea, and symptoms of congestive heart failure. Atrial and ventricular arrhythmias may occur in the scar tissue, producing palpitations, syncope, and even sudden death. A mural thrombus is often found (50%) [43, 44, 45, 50, 51, 52, 53].

Even if echocardiography is a useful diagnostic tool capable of identifying false aneurysm and assessing ventricular function, angiography and left ventriculography is the gold standard, estimating the size of aneurysm and evaluating cardiac function and kinesis, as well as coronary status. Tomographic three-dimensional echocardiography and magnetic resonance imaging are the most reliable means of evaluating left ventricular volume. Positron emission tomography (PET) can be helpful in an early phase to differentiate true aneurysm from hibernating myocardium with reversible dysfunction. Even magnetic resonance imaging can be useful, but cannot assess coronary anatomy.

Medical therapy aims to minimise the remodelling of the left ventricle: both in acute and chronic heart failure; ACE inhibitors may reduce ventricular wall stress, as well as ventricular dilatation. Beta-blockers do the same. Nitrates may reduce hypertrophy, but it seems they don't affect mortality.

Anticoagulation with warfarin is indicated for patients with a mural thrombus. Patients should be treated initially with intravenous heparin, with a target aPTT of 50–70 seconds. Warfarin is started simultaneously, and the INR target is 2–3 for a period of 3 to 6 months. The use of anticoagulation without the presence of a thrombus is controversial. Anticoagulation should be reinitiated if a new thrombus develops, and an echocardiographic follow up must be done [54].

Asymptomatic patients with a small aneurysm may be treated medically. However, an aneurysm that occupies more than 25% of the ventricular surface may significantly affect the global function. When refractory heart failure or ventricular arrhythmias are present, as well in the presence of a huge aneurysm, surgery is indicated.

Resection of the aneurysm may be followed by conventional closure or newer techniques to maintain LV geometry. In the plication technique, a direct closure of the aneurysm without excision is performed; this is usually done for very small aneurysms without internal thrombus [55]. Another conventional strategy, the linear repair, was first introduced by Cooley in 1958. In this technique, the incision is extended round the aneurysm leaving a rim of scar tissue and buttressed mattress sutures are placed successively. With this technique, changing ventricular geometry is possible [55].

Other newer techniques aim to maintain ventricular geometry by using the external patch (procedure performed by Daggett) or inverted T closure of ventriculotomy (as done by Komeda) [56], or circular patch technique for posterior aneurysms [57]. Finally, endoaneur-

ysmorrhaphy, a procedure proposed by Jatene, Dor, and Cooley, positions an endocardial patch in order to preserve both normal ventriculom and septal geometry [58, 59, 60].

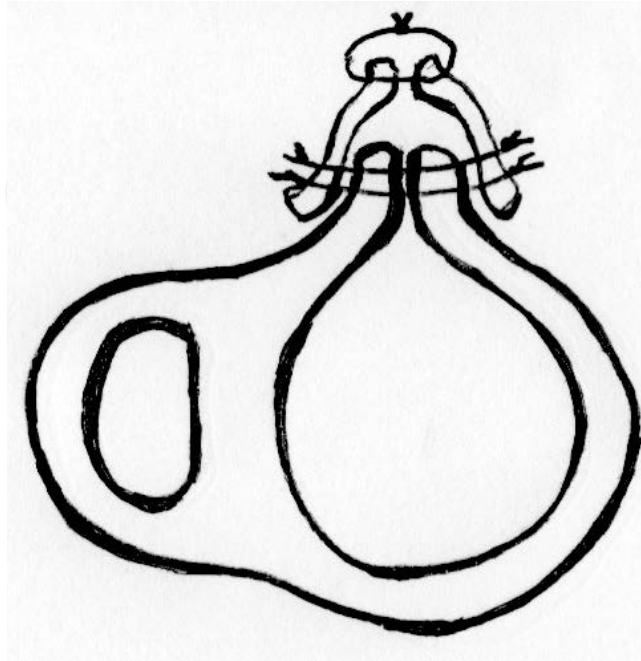


Figure 17. Traditional aneurismectomy: Linear closure [Adapted from Chikwe J, Beddow E, Glenville B. Cardiothoracic Surgery. Oxford University Press 2006]

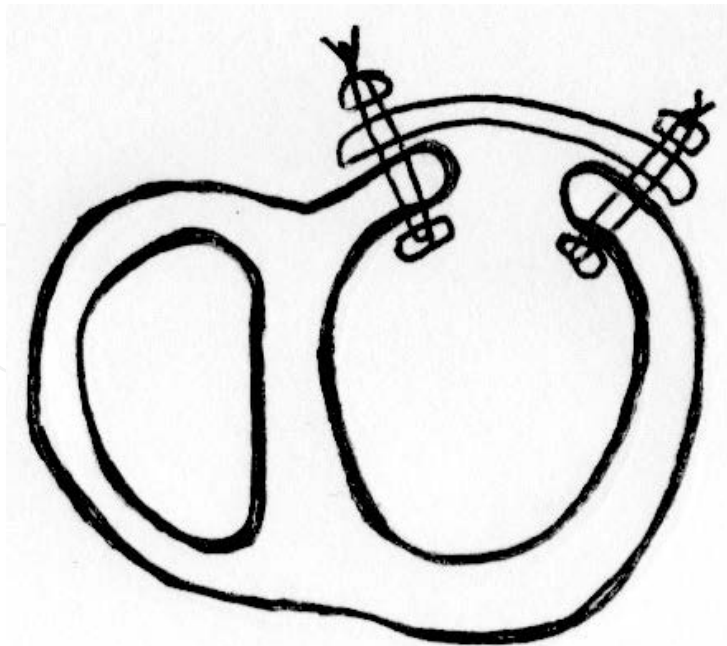


Figure 18. Traditional aneurismectomy: Patch closure [Adapted from Chikwe J, Beddow E, Glenville B. Cardiothoracic Surgery. Oxford University Press 2006]

7. Cardiogenic shock and heart failure

Cardiogenic shock is a clinical syndrome characterised by end-organ hypoperfusion, due to a rapid worsening of ventricular function.

It occurs in 5–8% of hospitalised patients with STEMI, and 12% of these cases are caused by a mechanical complication of myocardial infarction. Cardiogenic shock may also occur in 2.5% of non-coronary cases: any cause of acute, severe left or right ventricular dysfunction such as acute myopericarditis, tako-tsubo cardiomyopathy, hypertrophic cardiomyopathy, acute valvular regurgitation caused by endocarditis or chordal rupture due to trauma or degenerative disease, as well as aortic dissection, severe aortic or mitral insufficiency. Moreover, cardiac tamponade or massive pulmonary embolism may lead to this kind of shock [60, 61, 62, 63, 64].

Risk factors are directly related to the principal trigger. In the context of myocardial infarction, risk factors may include older age, hypertension, diabetes mellitus, multivessel coronary artery disease, prior myocardial infarction or angina, anterior location of infarction, prior diagnosis of heart failure, STEMI, and left bundle-branch block.

Considering the ischaemic aetiology of cardiogenic shock, pathological mechanism starts with the ischaemic injury of myocyte, with loss of effective contractility, and a systolic and diastolic dysfunction. A decrease in cardiac output leads to a decrease in systemic and coronary perfusion. A vicious cycle originates, with the worsening of hypoperfusion and the increasing of infarcted regions of myocardium. To compensate the decrease in stroke volume and cardiac output, sympathetic tone is increased, eliciting tachycardia, systemic vasoconstriction, and increased contractility of the healthy non-ischaemic myocardium. This results in an increase in the cardiac workload and oxygen consumption. When these compensatory mechanisms cannot meet the increased demand, there's once again a progression in myocardial injury. Even systemic inflammation may contribute to myocardial dysfunction, decreasing systemic perfusion. The spiral worsening of ventricular function and a subsequent shock was thought to occur after the loss of at least 40% of the left ventricular mass [60].

The definition of cardiogenic shock includes haemodynamic parameters, such as persistent hypotension (systolic blood pressure < 90 mmHg, with severe reduction in cardiac index < 1.8 L/min/m²), elevated filling pressure, and pulmonary capillary wedge pressure < 15 mmHg. Signs and symptoms include cool and sweaty extremities, cyanosis, decreased urine output, and/or alteration in mental status. Haemodynamic abnormalities go from mild hypoperfusion to profound shock, and the short-term outcome is directly related to the severity of the haemodynamic derangement [60, 61, 62, 63, 64].

The diagnosis is usually made with invasive haemodynamic monitoring using pulmonary artery catheterisation (Swan-Ganz catheter); however, Doppler echocardiography may help to confirm the elevation of the left ventricle filling pressures, and may assess mechanical causes of shock above all. ECG confirms ischaemic aetiology.

Therapies should not be delayed. On the pharmacological side, no drugs have been shown to improve survival, but they are fundamental in supporting and stabilising the patients prior to

the definitive therapy. Support includes inotropic and vasopressor agents, which should be used in the lowest possible doses (higher vasopressor doses are associated with poorer survival due to a combination between hemodynamic derangement and direct toxic effects).

IABP has long been a mainstay of mechanical therapy for cardiogenic shock [66, 67, 68, 69]. It improves coronary and peripheral perfusion via diastolic balloon inflation and augments left ventricular performance via systolic balloon deflation with an acute decrease in afterload. Nowadays, the reported efficacy of this mechanical support in studies has been variable; some studies, such as the IABP-SHOCK II trial have downgraded IABP, showing no significant differences in treatment groups [71]. Despite this fact, IABP remains in wide use, driven by substantial anecdotal evidence as well as meta-analytic results [70].

In the vicious cycle that characterises cardiogenic shock, revascularisation fulfills an important role, increasing the likelihood of survival with good quality of life (in the randomized SHOCK trial, a 13% increase in 1-year survival in patients assigned to early revascularisation was found) [30]. Mechanical reperfusion may be obtained with a percutaneous approach (angioplasty with or without stenting) or with surgical approach (coronary artery bypass grafting). The optimal revascularisation strategy for patients with multivessel coronary artery disease and cardiogenic shock is not clear. At large, immediate coronary artery bypass surgery is the preferred method of revascularisation when severe triple-vessel or left main disease is present, and should be performed when mechanical complications coexist. Percutaneous coronary intervention of the infarct-related artery is recommended in the case of single or double-vessel disease, or when surgery is not possible [60, 65]. In the STICH (Surgical Treatment for Ischaemic Heart Failure) trial, the addition of coronary artery bypass surgery to medical therapy reduced the most common modes of death (sudden death and fatal pump failure events), with beneficial effects principally seen after two years [72].

Temporary mechanical circulatory support may theoretically interrupt the vicious spiral of ischaemic damage, and allow for recovery of stunned and hibernating myocardium. This kind of support involves circulation of blood through a device that drains venous blood and returns it to the systemic arteries with pulsatile or continuous flow after passing a membrane oxygenator. The major limitations of temporary mechanical circulatory support are device-related complications and irreversible organ failure.

It is possible to distinguish between two main classes of devices with short-term and long-term support. Short-term devices are usually placed in patients with acute heart failure, with a refractory cardiogenic shock and/or mechanical complications of myocardial infarction.

Veno-arterial extra-corporeal membrane oxygenation (VA-ECMO) assists both ventricles and provides a continuous flow with maintenance of a pulsatile arterial pressure unless the circulation is completely supported by the cardio pulmonary bypass device. This pump may be beneficial in cases of severe cardiogenic shock refractory to other pharmacological and mechanical support measures, although its use has not been tested in randomised clinical trials. In a recent meta-analysis, it is shown that VA-ECMO provides acceptable short-term survival for adult patients with cardiogenic shock and stable long-term survival outcomes at up to 3 years. These benefits, however, must be considered alongside the significant associated risks in the decision to institute this type of haemodynamic support [73, 74].

Other short term supports are axial flow pumps, with pumps positioned across the aortic valve to provide active support by transvalvular left ventricle assistance, placed with percutaneous or peripheral surgical approach (e. g., The Impella Recover® - Impella CardioSystems GmbH, Aachen, Germany), and the left atrial-to-femoral arterial left ventricular assist devices, with percutaneously inserted transseptal and arterial cannulae connected to a centrifugal pump (e. g., The Tandem Heart™ pVAD - Cardiac Assist Technologies, Inc., Pittsburgh, PA, USA) [75].

Studies have shown that these mechanical supports may reverse haemodynamic and metabolic parameters in cardiogenic shock more effectively than with standard IABP treatment alone.

However, when end-stage heart failure occurs, cardiac transplantation remains the gold standard, even if the lack of suitable donor organs significantly limits this therapeutic option.

Implantation of a long-term ventricular assist device as a bridge to transplantation or as a destination therapy is an established life-sustaining treatment option for select patients [76, 77, 78, 79].

8. New therapeutic strategies against myocardial remodelling

As seen in the beginning of this chapter, at the bottom of any mechanical complication after a myocardial infarction is the process that starts with an ischaemic injury and finishes with the remodelling of the myocardial tissue. As a result of myocyte apoptosis, fibrous tissue deposition and the formation of a myocardial scar, heart failure occurs [2].

Although modest cardiomyocyte turnover occurs in the adult heart, it is insufficient for the restoration of a normal contractile function after substantial cardiomyocyte loss, and even if this cardiac remodelling can be slowed or sometimes reversed by intense pharmacological therapy (thrombolysis, ACEi, beta-blockers, and statins), this process is often progressive.

Several studies aim to find new therapeutic strategies for daily practise against myocardial remodelling. Many of them focused on biochemical patterns occurring during the remodelling process, principally on the ischaemic-reperfusion injury, by searching strategies against the generation of reactive oxygen species (ROS) in the ischaemic myocardium, or by interacting with complex cytokines pathways [80].

On the other hand, stem cells therapy seems to be another new approach to the problem of remodelling. Replacement and regeneration of functional cardiac muscle after an ischaemic insult co

uld be achieved by either stimulating proliferation of endogenous mature cardiomyocytes (reinitiating mitosis) or resident cardiac stem cells or by implanting exogenous donor-derived or allogeneic cardiomyocytes. New strategies may consist of transplanted bone marrow-derived cardiomyocyte or endothelial precursors, foetal cardiomyocytes, and skeletal myoblasts [81, 82, 83, 84].

Author details

Serena Mariani, Francesco Formica* and Giovanni Paolini

*Address all correspondence to: francesco_formica@fastwebnet.it

Cardiac Surgery Clinic, Department of Surgery and Translational Medicine, School of Medicine, University of Milan-Bicocca, San Gerardo Hospital, Monza (MB), Italy

References

- [1] Thygesen K, Alpert JS, Jaffe AS, Simoons ML, Chaitman BR, White HD: The Writing Group on behalf of the Joint ESC/ACCF/AHA/WHF Task Force for the Universal Definition of Myocardial Infarction - Third Universal Definition of Myocardial Infarction. *JACC*. 2012;60(16):1581-98.
- [2] Schoen FJ. The heart. In: Kumar V, Abbas AK, Fausto N. *Robbins and Cotran Pathologic Bases of Disease*, 7th edition. 2006;575-585.
- [3] Marques JS, Jorge C, Feija A, Diogo AN. Acute myocardial infarction complication diagnosed by three-dimensional echocardiography. *European Journal of Echocardiography*. 2011;12:E29.
- [4] Harmony R, Reynolds HR, Hochman JS. Heartbreak. *European Heart Journal*. 2010;31:1433-1435.
- [5] Hatcher CR Jr, Mansour K, Logan WD Jr, et al. Surgical complications of myocardial infarction. *Am Surg*. 1970;36(3):163-170.
- [6] FitzGibbon GM, Hooper GD, Heggveit HA. Successful surgical treatment of postinfarction external cardiac rupture. *J Thorac Cardiovasc Surg*. 1972;63(4):622-630.
- [7] Figueras J, Cortadellas J, Soler-Soler J. Left ventricular free wall rupture: Clinical presentation and management. *Heart*. 2000;83:499e504.
- [8] Kumar Mishraa P, Pathib V, Murdaya A. Post myocardial infarction left ventricular free wall rupture. *Interactive Cardiovascular and Thoracic Surgery* 6. 2007;39-42.
- [9] Becker RC, Gore JM, Lambrew C, Weaver WD, Rubison RM, French WJ. A composite view of cardiac rupture in the United States National Registry of Myocardial Infarction. *J Am Coll Cardiol*. May 1996;27(6):1321-6.
- [10] Kleiman NS, Terrin M, Mueller H, Chaitman B, Roberts R, Knatterud GL. Mechanisms of early death despite thrombolytic therapy: Experience from the Thrombolysis in Myocardial Infarction Phase II (TIMI II) study. *J Am Coll Cardiol*. May 1992;19(6):1129-35.

- [11] Wehrens XHT, Doevendans PA. Cardiac rupture complicating myocardial infarction. *Int J Cardiol.* 2004;95:285e92.
- [12] Perdigao C, Andrade A, Ribeiro C. Cardiac rupture in acute myocardial infarction: Various clinico-anatomical types in 42 recent cases observed over a period of 30 months. *Arch Mal Coeur Vaiss.* 1987;80(3):336-334.
- [13] Becker AE, van Mantgem JP. Cardiac tamponade: A study of 50 hearts. *Eur J Cardiol.* 1975;3(4):349-358.
- [14] Van Tassel RA, Edwards JE. Rupture of heart complicating myocardial infarction: Analysis of 40 cases including nine examples of left ventricular false aneurysm. *Chest.* 1972;61(2):104-106.
- [15] Nihoyannopoulos P, Kisslo, editors. *Echocardiography.* 2009. doi: 10.1007/978-1-84882-293-1.
- [16] Holubeca T, Caliskana E, Bettex D, Maisano F. Repair of post-infarction left ventricular free wall rupture using an extracellular matrix patch. *Oxford University Press on behalf of the European Association for Cardio-Thoracic Surgery.* 2015.
- [17] Mantovani V, Vanoli D, Chelazzi P, Leporel V, Ferrarese S, Sala A. Post-infarction cardiac rupture: Surgical treatment. *European Journal of Cardio-thoracic Surgery* 22. 2002;777-780.
- [18] Chen SSM, Ruengsakulrach P, Dick RJL, Buxton BF. Post-infarct left ventricular free wall rupture – not always a lethal complication of acute myocardial infarction. *Heart Lung and Circulation.* 2004;13:26-30.
- [19] Mundth ED. Rupture of the Heart Complicating Myocardial Infarction. *Circulation.* 1972;46:427-429.
- [20] Reardon MJ, Carr CL, Diamond A, Letsou GV, Safi HJ, Espada R, Baldwin JC. Ischemic left ventricular free wall rupture: Prediction, diagnosis, and treatment. *Ann Thorac Surg.* 1997;64:1509-13.
- [21] Iemura J, Oku H, Otaki M, Kitayama H, Inoue T, Kaneda T. Surgical strategy for left ventricular free wall rupture after acute myocardial infarction. *Ann Thorac Surg.* 2001;71:201-4.
- [22] Canovasa SJ, Limb E, Horneroa F, Monteroa J. Surgery for left ventricular free wall rupture: patch glue repair without extracorporeal circulation. *European Journal of Cardio-thoracic Surgery.* 2003;23:639-641.
- [23] Fujimatsu T, Oosawa H, Takai F, Aruga M, Ogiwara F, Mawatari E, Sakurai S. Patch-and-Glue sutureless repair for blowout rupture after myocardial infarction: Report of two cases. *Ann Thorac Cardiovasc Surg.* 2008;14(1).
- [24] Harrison W, Ruygrok PN, Greaves S, Wijesinghe N, Charleson H, Wade C, Devlin G. Percutaneous closure of left ventricular free wall rupture with associated false aneurysm to prevent cardioembolic stroke. *Heart, Lung and Circulation.* 2008;17:243-263.

- [25] Latham PM. Lectures on subjects connected with clinical medicine comprises disease of the heart. London: Longman Rees; 1845.
- [26] Deja MA, Szostek J, Widenka K, Szafron B, Spyt TJ, Hickey MSJ, Sosnowski AW. Post infarction ventricular septal defect: can we do better? *European Journal of Cardio-thoracic Surgery*. 2000;18:194-201.
- [27] Lemery R, Smith HC, Giuliani ER, Gersh BJ. Prognosis in rupture of the ventricular septum after acute myocardial infarction and role of early surgical intervention. *Am J Cardiol*. 1992;70(2):147-151.
- [28] Agnihotri AK, Madsen JC, Daggett WM. Surgical treatment for complications of acute myocardial infarction: postinfarction ventricular septal defect and free wall rupture. In: Cohn LH, Edmunds LH Jr. *Cardiac Surgery in the Adult*. 2003;681-734.
- [29] Crenshaw BS, Granger CB, Birnbaum Y, Pieper KS, Morris DC, Kleiman NS. Risk factors, angiographic patterns, and outcomes in patients with ventricular septal defect complicating acute myocardial infarction. GUSTO-I (Global Utilization of Streptokinase and TPA for Occluded Coronary Arteries) Trial Investigators. *Circulation*. Jan 4-11 2000;101(1):27-32.
- [30] Menon V, Webb JG, Hillis LD, et al. Outcome and profile of ventricular septal rupture with cardiogenic shock after myocardial infarction: a report from the SHOCK Trial Registry. SHould we emergently revascularize Occluded Coronaries in cardiogenic shock? *J Am Coll Cardiol*. Sep 2000;36(3 Suppl A):1110-6.
- [31] Cooley DA, Belmonte BA, Zeis LB, Schnur S. Surgical repair of ruptured interventricular septum following acute myocardial infarction. *Surgery*. 1957;41-930.
- [32] Heimbacker RO, Legmire G, Chen C. Surgery for massive myocardial infarction. An experimental study of emergency infarctectomy with a preliminar report on the clinical application. *Circulation*. 1968;37(Suppl 4):II3-II1.
- [33] Daggett WM, Buckley MJ, Akins CW. Improved results of surgical management of postinfarction ventricular septal rupture. *Ann Surg*. 1982;196(3):269-277.
- [34] Miyajima M, Kawashima T, Saito T, Yokoyama H, Ohori K, Kuwaki K, Sasaki A, Higami T. Delayed closure of postinfarction ventricular septal rupture. *Ann Thorac Cardiovasc Surg*. 2010; 16(2).
- [35] Ari H, Melek M, Ari S, Doganay K, Cosar Oztas S. Percutaneous closure of post-myocardial infarction ventricular septal rupture in patients with ventricular septal rupture and apical thrombus: First case in literature. *International Journal of Cardiology*. 2015;182:487-490.
- [36] Bouma W, Wijdh-den Hamer IJ, Klinkenberg TJ, Kuijpers M, Bijleveld A, van der Horst ICC, Erasmus ME, Gorman III JH, Gorman RC, Mariani MA. Mitral valve repair for post-myocardial infarction papillary muscle rupture. *European Journal of Cardio-Thoracic Surgery*. 2013;44:1063-1069.

- [37] Bouma W, Wijdh-den Hamer IJ, Koene BM, Kuijpers M, Natour E, Erasmus ME, Jainandunsing JS, van der Horst ICC, Gorman III JH, Gorman RC, Mariani MA. Long-term survival after mitral valve surgery for post-myocardial infarction papillary muscle rupture. *Journal of Cardiothoracic Surgery*. 2015;10:11.
- [38] Ming Ming Sim. Giant V wave in an obscured acute mitral regurgitation due to rupture of the papillary muscle. *A712 JACC*. March 17 2015;65(Issue 10S).
- [39] Ranganathan N, Burch GE. Gross morphology and arterial supply of the papillary muscles of the left ventricle of man. *Am Heart J*. 1969;77(4):506-516.
- [40] Connell JM, Worthington A, Chen FY, Shernan SK. Ischemic mitral regurgitation mechanisms, intraoperative echocardiographic evaluation, and surgical considerations. *Anesthesiology Clin*. 2013;31:281-298.
- [41] Formica F, Corti F, Sangalli F, Greco P, Ferro O, Colagrande L, Paolini G. Mitral valve annuloplasty with a semirigid annuloplasty band in ischemic mitral regurgitation: Early results. *Journal of Cardiovascular Medicine*. 2007;8:499-503.
- [42] Calafiore AM, Iacò AL, Clemente D, Refaie R, Romano S, Asif M, Penco M, Di Mauro M. Repair or prosthesis insertion in ischemic mitral regurgitation: Two faces of the same medal. *IJC Heart & Vessels*. 2014;3:32-36.
- [43] Talwar S, Jayanthkumar HV, Kumar AS. Chordal preservation during mitral valve replacement: Basis, techniques and results. *IJT CVS*. 2005;21:45-52.
- [44] Thompson CR, Buller CE, Sleeper LA, Antonelli TA, Webb JG, Jaber WA, Abel JG, Hochman JS. Cardiogenic shock due to acute severe mitral regurgitation complicating acute myocardial infarction: a report from the SHOCK Trial Registry. *J Am Coll Cardiol*. 2000;36:1104-9.
- [45] Aguiar J, del Mar Barba M, Alba Gil J, Caetano J, Ferreira A, Nobre A, Cravino J. Aneurisma do ventrículo esquerdo e diagnóstico diferencial com pseudoaneurisma. *Rev Port Cardiol*. 2012. doi:10.1016/j.repc.2012.04.001.
- [46] Sutton MG, Sharpe N. Left ventricular remodeling after myocardial infarction: Pathophysiology and therapy. *Circulation*. 2000;101(25):2981-2988.
- [47] Kumar Das A, Wilson GM, Furnary AP. Coincidence of true and false left ventricular Aneurysm. *Ann Thorac Surg*. 1997;64:831-4.
- [48] Forman MB, Collins HW, Kopelman HA, Vaughn WK, Perry JM, Virmani R, Freisinger GC. Determinants of left ventricular aneurysm formation after anterior myocardial infarction: A clinical and angiographic study. *JACC*. December 1986;8(6):1256-62.
- [49] Tikiz H, Atak R, Balbay Y, Genc Y, Kutuk E. Left ventricular aneurysm formation after anterior myocardial infarction: clinical and angiographic determinants in 809 patients. *International Journal of Cardiology*. 2002;82:7-14.

- [50] Heatlie GJ, Mohiddin R. Left ventricular aneurysm: Comprehensive assessment of morphology, structure and thrombus using cardiovascular magnetic resonance. *Clinical Radiology*. 2005;60:687-692.
- [51] Chao HH, Lu MJ, Hung CR. Spontaneous rupture of left ventricular true aneurysm. *Ann Thorac Surg*. 2005;80:1106-8.
- [52] Arsan S, Akgun S, Turkmen M, Kurtoglu N, Yildirim T. Delayed rupture of a postinfarction left ventricular true aneurysm. *Ann Thorac Surg*. 2004;77:1813-5.
- [53] Hirota M, Omoto T, Ishikawa N, Fukuzumi M, Ohno M, Tedoriya T. Surgical strategy for subepicardial aneurysm: Two case reports. *Ann Thorac Cardiovasc Surg*. 2010;16:291-293.
- [54] Kutty RS, Jones N, Moorjani N. Mechanical complications of acute myocardial infarction. *Cardiol Clin*. 2013;31:519-531. doi:10.1016/j.ccl.2013.07.004.
- [55] Mills NL, Everson CT, Hockmuth DR. Technical advances in the treatment of left ventricular aneurysm. *Ann Thorac Surg*. 1993;55(3):792-800.
- [56] Komeda M, David TE, Malik A, et al. Operative risks and long-term result of operation for left ventricular aneurysm. *Ann Thorac Surg*. 1992;53(1):22-28;discussion 8-9.
- [57] Glower DD, Lowe JE. Left ventricular aneurysm. In: Cohn LH, Edmunds LH Jr. *Cardiac Surgery in the adult*. New York: Mc-Graw Hill; 2003:771-788.
- [58] Jatene AD. Left ventricular aneurysmectomy. Resection or reconstruction. *J Thorac Cardiovasc Surg*. 1985;89(3):321-331
- [59] Dor V, Saab M, Coste P, et al. Endoventricular patch plasties with septal exclusion for repair of ischemic left ventricle: Technique, results and indications from a series of 781 cases. *Jpn J Thorac Cardiovasc Surg*. 1998;46(5):389-398.
- [60] Cooley DA, Frazier OH, Duncan JM, et al. Intracavitary repair of ventricular aneurysm and regional dyskinesia. *Ann Surg*. 1992;215(5):417-423; discussion 23-24.
- [61] Reynolds HR, Hochman JS. Cardiogenic shock current concepts and improving outcomes. *Circulation*. 2008;117:686-697.
- [62] Hochman JS, Buller CE, Sleeper LA, Boland J, Dzavik V, Sanborn TA, Godfrey E, White HD, Lim J, LeJemtel T. Cardiogenic shock complicating acute myocardial infarction—Etiologies, management and outcome: A Report from the SHOCK Trial Registry. *JACC*. September 2000;36 (3 Suppl A):1063-70.
- [63] Kaminski KA, Tycinska AM, Stepek T, Szpakowicz A, Oledzka E, Dobrzycki S, Musiał WJ. Natural history and risk factors of long-term mortality in acute coronary syndrome patients with cardiogenic shock. *Advances in Medical Sciences*. 2014;59:156-160.
- [64] Morici N, Sacco A, Paino R, Oreglia JA, Bottiroli M, Senni M, Nichelatti M, Canova P, Russo C, Garascia A, Kulgmann S, Frigerio M, Oliva F. Cardiogenic shock: How to

overcome a clinical dilemma. Unmet needs in Emergency Medicine. *International Journal of Cardiology*. 2015. doi:10.1016/j.ijcard.2015.02.111.

- [65] Babaev A, Frederick PD, Pasta DJ, Every N, Sichrovsky T, Hochman JS. Trends in management and outcomes of patients with acute myocardial infarction complicated by cardiogenic shock. *JAMA*. July 27 2005;294(4).
- [66] Goldberg RJ, Gore JM, Alpert JS, Osganin V, de Groot J, Bade J, Chen Z, Frid D, Dalen JE. Cardiogenic shock after acute myocardial infarction. Incidence and mortality from a community-wide perspective, 1975 to 1988. *N Eng J Med*. 1991;325:1117-22.
- [67] Jensen JK, Thayssen P, Antonsen L, Hougaard M, Junker A, Pedersen KE, Jensen LO. Influence of cardiogenic shock with or without the use of intra-aortic balloon pump on mortality in patients with ST-segment elevation myocardial infarction. *IJC Heart & Vasculature*. 2015;6:19-24.
- [68] Trost JC, Hillis LD. Intra-aortic balloon counterpulsation. *Am J Cardiol*. 2006;97:1391e8.
- [69] White JM, Ruygrok PN. Intra-aortic balloon counterpulsation in contemporary practice – where are we? *Heart, Lung and Circulation*. 2015;1-7.
- [70] Cassese S, de Waha A, Ndrepepa G, Ranftl S, King L, Schomig A, Kastrati A. Intra-aortic balloon counterpulsation in patients with acute myocardial infarction without cardiogenic shock. A meta-analysis of randomized trials. *Am Heart J*. 2012;164:58-65.e1.
- [71] Thiele H, Schuler G, Neumann F-J, Hausleiter J, Olbrich H-G, Schwarz B, Hennersdorf M, Empen K, Fuernau G, Desch S, de Waha S, Eitel I, Hambrecht R, Bohm M, Kurowski V, Lauer B, Minden H-H, Figulla H-R, Braun-Dullaeus RC, Strasser RH, Rochor K, Maier SKJ, Mollmann H, Schneider S, Ebelt H, Werdan K, Zeymer U. Intraaortic balloon counterpulsation in acute myocardial infarction complicated by cardiogenic shock: Design and rationale of the Intraaortic Balloon Pump in Cardiogenic Shock II (IABP-SHOCK II) trial. *Am Heart J*. 2012;163:938-45.
- [72] Carson P, Wertheimer J, Miller A, O'Connor CM, Pina IL, Selzman C, Sueta C, She L, Greene D, Lee KL, Jones RH, Velazquez EJ. The STICH Trial (Surgical Treatment for Ischemic Heart Failure). *JCHF*. 2013;1(5):400-408. doi:10.1016/j.jchf.2013.04.012.
- [73] Formica F, Avalli L, Colagrande L et al. Extracorporeal membrane oxygenation to support adult patients with cardiac failure: predictive factors of 30-day mortality. *Interact Cardiovasc Thorac Surg*. 2010 May;10(5):721-6.
- [74] Pujara D, Sandoval E, Simpson L, Mallidi HR, Singh SK. The State of the Art in Extra Corporeal Membrane Oxygenation. *Semin Thoracic Surg*, <http://dx.doi.org/10.1053/j.semtcvs.2015.02.004>.

- [75] Thiele H, Smalling RW, Schuler GC. Percutaneous left ventricular assist devices in acute myocardial infarction complicated by cardiogenic shock. *European Heart Journal*. 2007;28:2057-2063.
- [76] White CW, Chelvanathan A, Zieroth S, Cordova-Perez F, Menkis AH, Freed DH. Can long-term ventricular assist devices be safely implanted in low-volume, non-heart transplant centres? *Canadian Journal of Cardiology*. 2013;29:983-989.
- [77] McIlvennan CK, Matlock DD, Narayan MP, Nowels C, Thompson JS, Cannon A, Bradley WJ, Allen LA. Perspectives from mechanical circulatory support coordinators on the pre-implantation decision process for destination therapy left ventricular assist devices. *Heart & Lung*. 2015;1e6.
- [78] Morris RJ, Shore ED. Pro: LVAD: Patient's desire for termination of vad therapy should be challenged. *Journal of Cardiothoracic and Vascular Anesthesia*. October 2013;27(50):1048-1050.
- [79] Hirose H, Amano A, Yoshida S, Nagao T, Sunami H, Takahashi A, Nagano N. Surgical management of unstable patients in the evolving phase of acute myocardial infarction. *Ann Thorac Surg*. 2000;69:425-8.
- [80] Florian A, Ludwig A, Rosch S, Yildiz H, Klumpp S, Sechtem U, Yilmaz A. Positive effect of intravenous iron-oxide administration on left ventricular remodelling in patients with acute ST-elevation myocardial infarction – A cardiovascular magnetic resonance (CMR) study. *International Journal of Cardiology*. 2014;173:184-189.
- [81] Sheu Jiunn-Jye, Lee Fan-Yen, Yuen Chun-Man, Chen Yi-Ling, Huang Tien-Hung, Chua Sarah, Chen Yung-Lung, Chen Chih-Hung, Chai Han-Tan, Sung Pei-Hsun, Chang Hsueh-Wen, Sun Cheuk-Kwan, Yip Hon-Kan, Combined Therapy with Shock Wave and Autologous Bone Marrow-Derived Mesenchymal Stem Cells Alleviates Left Ventricular Dysfunction and Remodeling through Inhibiting Inflammatory Stimuli, Oxidative Stress & Enhancing Angiogenesis in a Swine Myocardial Infarction Model. *International Journal of Cardiology*. 2015. doi:10.1016/j.ijcard.2015.03.044.
- [82] Itescu S, Schuster MD, Kocher AA. New directions in strategies using cell therapy for heart disease. *J Mol Med*. 2003;81:288-296. doi:10.1007/s00109-003-0432-0.
- [83] Chen J, Guo R, Zhou Q, Wang T. Injection of composite with bone marrow-derived mesenchymal stem cells and a novel synthetic hydrogel after myocardial infarction: A protective role in left ventricle function. *Kaohsiung Journal of Medical Sciences*. 2014;30:173e180.
- [84] Zhong Ye, Bi-Li Zhang, Xian-Xian Zhao, Yong-Wen Qin, Hong Wu, Jiang Cao, Jian-Liang Zhang, Jian-Qiang Hu, Xing Zheng, Rong-Liang Xu. Intracoronary infusion of bone marrow-derived mononuclear cells contributes to longstanding improvements of left ventricular performance and remodelling after acute myocardial infarction: A meta-analysis. *Heart, Lung and Circulation*. 2012;21:725-733.