

## Colonic Obstruction from Renal Cell Carcinoma Metastasis After 21 Years: Report of a Case and Review of the Literature

Guttadauro A<sup>1\*</sup>, Maternini M<sup>1</sup>, Macchini D<sup>2</sup>, Ripamonti L<sup>1</sup>, Festa A<sup>3</sup>, Chiarelli M<sup>4</sup> and Gabrielli F<sup>1</sup>

<sup>1</sup>Department of General Surgery, University of Milano-Bicocca, Istituti Clinici Zucchi, Monza, Italy

<sup>2</sup>Department of General Surgery, University of Milano-Bicocca, Ospedale San Gerardo Monza, Italy

<sup>3</sup>Department of Anatomic-Pathological, Policlinico San Donato, Milano, Italy

<sup>4</sup>Department of General Surgery, Ospedale di Lecco, Lecco, Italy

### 1. Abstract

**1.1. Background:** Renal cell carcinoma may recur with distant localization many years after surgery, even if specimen histology is favorable. Symptoms of presentation are similar to those of primary neoplasm but radiology and biopsy can be diriment.

**1.2. Case Presentation:** We report the case of a 72-year old male who underwent sigmoid resection due to intestinal obstruction by a metachronous metastasis from renal cell carcinoma, 21 years after primitive tumor curative resection.

**1.3. Conclusion:** Colonic metastasis from renal cell carcinoma is possible even after 21 years.

Received Date: 08 Feb 2019  
Accepted Date: 21 Feb 2019  
published Date: 25 Feb 2019

**Citation:** Guttadauro A (2019) Colonic Obstruction from Renal Cell Carcinoma Metastasis After 21 Years: Report of a Case and Review of the Literature- *Universal Journal of Surgery*. Vol (1): Issue (2): 1-3

### 2. Keywords

Neoplasms; Histologies; Immunohistochemistry

### 3. Background

In the colon and rectum, metastasis from haematogenous origin, unlike the small bowel, is less common than primary neoplasms [1]. Berge and Lundberg provided lots of data from a 10-year study involving 16.000 autopsies: in their work, 62 cases of malignancies to the colon and rectum were identified, 14 of which of lung origin and 10 from the breast [2]. [1] reported in a multi-institutional study a higher incidence in the left colon, followed by the right colon, the transverse colon and the rectum. In 35 cases included in the study, the most common primary tumor was breast carcinoma (n=17), followed by melanoma (n=7), sarcoma (n=4), lung carcinoma (n=4), renal cell carcinoma (n=2) and Merkel cell carcinoma (n=1) [1]. Metastases to the

colon from ovarian carcinoma were also reported [3].

Malignancies to colorectal wall can be the consequence of different pathways, like direct invasion along the fasciae and the mesentery, peritoneal seeding and blood stream [4,5].

Clinical manifestation are similar to those of primary neoplasms and may be change in bowel habit, bleeding, abdominal pain, anorexia, nausea, obstruction and perforation, but lots of cases are asymptomatic at the time of diagnosis [1,4-10].

Colonoscopy and radiologic findings rarely can differentiate primitive tumors from metastasis of other origin, but some features may be useful for the differential diagnosis, which requires histological examination. For example the presence of a precursor lesion at the edge of the tumor, regional lymph node involvement and histological demonstration of the mucosa involvement are

\*Corresponding author: Angelo Guttadauro, Department of General Surgery, University of Milano-Bicocca, Italy Tel: (039) 3396680797, E-mail: angelo.guttadauro@unimib.it

typical of the firmer, while the latter often form multiple serosa based lesions that spare the mucosa and patients have history of previous other neoplasia (often already metastatic) [11-13].

The typical aspect of the specimen is a polypoid lesion, while nodule, ulceration and diffuse thickness occur less frequently. Immunohistochemistry is generally necessary [1] and depending on gross and microscopically aspect it can comprehend stains for CK7, CK20, TTS-1, CDX-2, S100, HMB45, WT-1, ER, PR, CD 10 and vimentin [11,14].

The Disease-Free Interval and the Mean Survival Time are different according to histologic type (the longest ones for melanoma and the shortest ones for kidney) [1,7].

Here, we present a case of colonic obstruction due to a metachronous localization from Renal Cell Carcinoma (RCC), 21 years after surgery for the primitive tumor.

#### 4. Case Report

A 72-year-old male came to our emergency department for intestinal obstruction, complaining worsening constipation and haematochezia during the last month. The patient had undergone a right nephrectomy 21 years before for a RCC. No adjuvant therapy was given and no signs of recurrence were detected since 20 years later, when multiple metastasis involving the pleura (with ematic effusion) and osteolytic metastasis to left scapula and right head of the omerus were identified. He undergone talc pleurodesis, radiotherapy for bone localization and immunotherapy with bevacizumab was started. CT-scan at the admission showed a colliquative lesion on the head of the pancreas and a marked dilatation of the right and transversus colon until the splenic flexure where a ipercaptant mass of 6 cm were present. Hemoglobin concentration was 9.5 g/dL.

After resolution of obstruction by conservative treatment, a colonoscopy was performed, showing an obstructive ulcerated and bleeding mass involving the sigmoid wall, 30 cm from the anal verge. No biopsy was performed due to the hemorrhage status and for the same reason the patient was addressed to surgery instead of endoscopic stenting: intraoperative findings showed a 7cm mass involving the sigmoid intestine, with high vascularized neoplastic adhesions to the parietal peritoneum. Dilation of prestenotic colon was modest, so sigmoid resection with primary anastomosis was performed. Postoperative was regular and he was discharged after 9 days. Histology and immunohistochemistry revealed a full-thickness clear cells neoplasm localization involving the sigmoid wall (**Figure 1,2**). During the follow-up

no signs of bowel recrudescence were identified and the patient died 13 months later due to neoplastic cachexia.

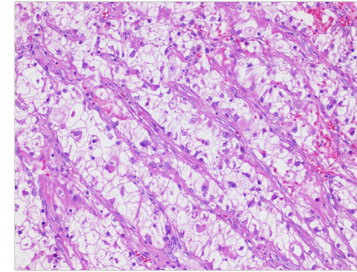


Figure 1: full-thickness clear cells neoplasm localization involving the sigmoid wall

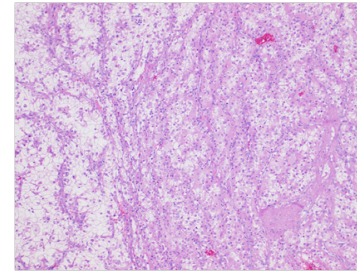


Figure 2: full-thickness clear cells neoplasm localization involving the sigmoid wall

#### 5. Discussion

RCC count for 3% of adult malignancies and has a slight higher incidence in men [15]. Most of cases occur at 50-70 years of age and 30% have metastasis at the time of diagnosis. Metastasis mostly involve lung, liver and bone and less frequently brain, skin and soft tissues. Metachronous metastases are generally identified in the first two years after nephrectomy [16,17], but long-term Disease-Free interval followed by metastatic findings are also reported [18]. Distant localization of the kidney to colonic or rectal wall were previously reported and are rare occurrence [7,10,16].

Different cases where solitary malignancies to the bowel were diagnosed many years after surgery for primitive tumor were reported, both for RCC [7] and for other histologies (mostly breast carcinoma) [1,19,20,21].

Clinical presentation is indistinguishable from primitive colonic tumors and the diagnosis should be considered in patients with past history of RCC, anyway biopsy should be obtained when feasible, for histology.

If the metastatic localization induces life-threatening consequences, surgery could be proposed while other cases should be considered singularly. However, surgical resection of solitary metastasis from RCC was reported to improve survival rates and disease-free interval [22].

## 6. Conclusion

In conclusion, colonic obstruction due to metachronous metastasis from RCC may benefit from resection even in the presence of other secondary localization.

## References

- Mourra N, Jouret-Mouin A, Lazure T et al. Metastatic Tumors to the Colon and Rectum. *Arch Pathol Lab Med.* 2012; 136(11): 1397-1401.
- Berge T, Lundberg S. Cancer in Malmö 1958-1969: an autopsy study. *Acta Pathol Microbiol Scand Suppl.* 1977; 260: 1-235.
- Feller E, Schiffman FJ. Colonic obstruction as the first manifestation of ovarian carcinoma. *Am J Gastroenterol.* 1987; 85: 25-28.
- Caramella E, Bruneton JN, Roux P, Aubanel D, Lecomte P. Metastases of the digestive tract: report of 77 cases and review of the literature. *Eur J Radiol.* 1983; 3(4): 331-338.
- Feczko PJ, Collins DD, Mezwa DG. Metastatic disease involving the gastrointestinal tract. *Radiol Clin North Am.* 1993; 31(6): 1359-1373.
- Rees BI, Okwonga W, Jenkins IL. Intestinal metastases from carcinoma of the breast. *Clin Oncol.* 1976; 2(2): 113-119.
- Graham AP. Malignancy of the kidney: survey of 195 cases. *J Urol.* 1947; 58: 10.
- Cifuentes N, Pickren JW. Metastases from carcinoma of mammary gland: an autopsy study. *J Surg Oncol.* 1979; 11(3): 193-205.
- Taal BG, Den Harlog Jager FCA, Steinmetz R, Peterse H. The spectrum of gastrointestinal metastases of breast carcinoma: II. The colon and rectum. *Gastrointest Endosc.* 1992; 38(2): 136-141.
- Harris M, Howell A, Chorissouhou M, Swindell RIC, Hudson M, Sellwood RA. A comparison of the metastatic pattern of infiltrating lobular carcinoma and infiltrating duct carcinoma of the breast. *Br J Cancer.* 1984; 50(1): 23-30.
- Shoemaker CP, Hoyle CL, Levine SB, Farman J. Late solitary colonic recurrence of renal carcinoma. *Am J Surg.* 1970; 120(1): 99-100.
- Estrella JS, Wu TT, Rashid A, Abraham SC. Mucosal colonization by metastatic carcinoma in the gastrointestinal tract: a potential mimic of primary neoplasia. *Am J Surg Pathol.* 2011; 35(4): 563-72.
- Fenoglio-Preiser CM, Noffsinger AE, Stemmermann GN, et al. eds. *Gastrointestinal Pathology An Atlas and Text.* Philadelphia: Lippincott Williams and Wilkins; 2008.
- Karahan N, Bozkurt KK, Cırıř IM, Songür Y, Akin M, Cetin M, et al. Duodenojejunal invagination caused by small bowel metastasis of renal cell carcinoma. *Turk J Gastroenterol.* 2011; 22(3): 355-7.
- Cohen HT, McGovern FJ. Renal-cell carcinoma. *N Engl J Med* 2005; 353: 2477-2490.
- Valdespino-Castillo VE, Ruiz-Jaime A. Renal cell carcinoma with colon metastases: an infrequent site for metastases. *Cir Cir.* 2008 Jul-Aug; 76(4): 339-42.
- Chung PH, Srinivasan R, Linehan WM, Pinto PA, Bratslavsky G. Renal cell carcinoma with metastases to the gallbladder: four cases from the National Cancer Institute (NCI) and review of the literature. *Urol Oncol* 2012; 30: 476-481.
- Giuliani L1, Giberti C, Martorana G, Rovida S. Radical extensive surgery for renal cell carcinoma: long-term results and prognostic factors. *J Urol* 1990; 143: 468-74.
- Amin AA, Reddy A, Jha M, Prasad K. Rectal metastasis from breast cancer: an interval of 17 years. *BMJ Case Rep.* 2011.
- Théaux J, Bretagnol, Guedj N, Cazals-Hatem D, Panis Y. Colorectal breast carcinoma metastasis diagnosed as an obstructive colonic primary tumor. A case report and review of the literature. *Gastroenterol Clin Biol.* 2009; 33(12): 1114-7.
- Nikkar-Esfahani A, Kumar BG, Aitken D, Wilson RG. Metastatic breast carcinoma presenting as a sigmoid stricture: report of a case and review of the literature. *Case Rep Gastroenterol.* 2013 ;7(1): 106-11
- Leslie KA, Tsao JI, Rossi RL, Braasch JW: Metastatic renal cell carcinoma to ampulla of Vater: an unusual lesion amenable to surgical resection. *Surgery* 1996; 119: 349-351.