

Ischemia and perforation of Meckel's diverticulum presenting with intestinal obstruction

Pinotti Enrico*; Romano Fabrizio; Degrate Luca; Uggeri Fabio

*Pinotti Enrico

University of Milano Bicocca, San Gerardo Hospital, Via Pergolesi 33, 20900 Monza, Italy
Phone: + 39-039-2333651; Email: enricopinotti@hotmail.it

Description

Meckel's diverticulum has an incidence of 2-4% and it is usually asymptomatic. It may become clinically evident in the presence of complications such as haemorrhage, obstruction or diverticulitis [1]. We here report the case of a 29 years old patient that was admitted to our emergency department with intestinal obstruction. At blood samples WBC was 4.500/ μ L [4.000-11.000] and CRP was 41 mg/dl [<0.5]. CT scan found an intestinal obstruction with the evidence of inflammation of a small bowel diverticulum (Figure 1). Patient underwent laparotomy: At surgical exploration an ischaemic and perforated Meckel's diverticulum was found and resected (Figure 2).

Postoperative course was uneventful, patient was treated with antibiotic therapy with Piperacillin/Tazobactam and was discharge after 8 days. Meckel's diverticulum is a rare cause of bowel obstruction and CT scan can be usefull for diagnosis of this condition [2].

Figures

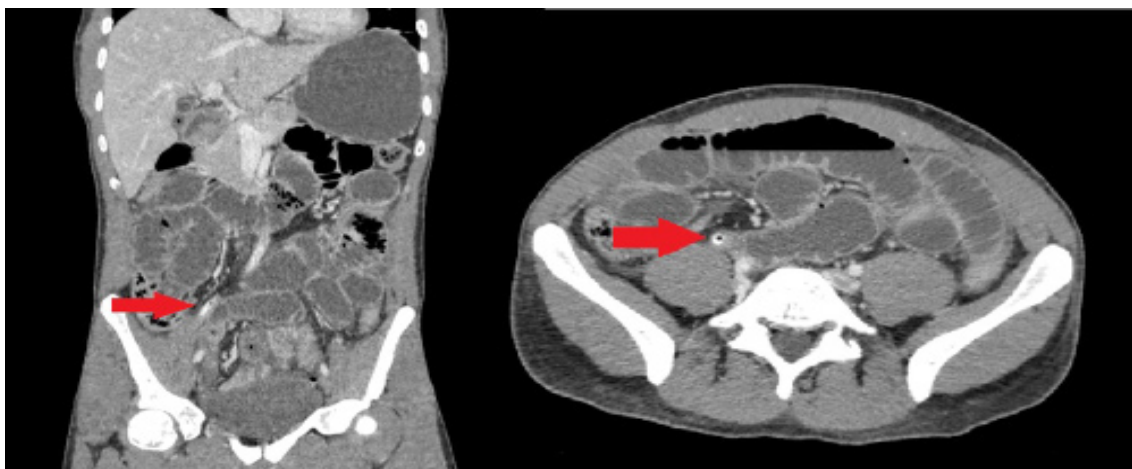

Figure 1: CT scan. Arrow: Meckel's Diverticulum

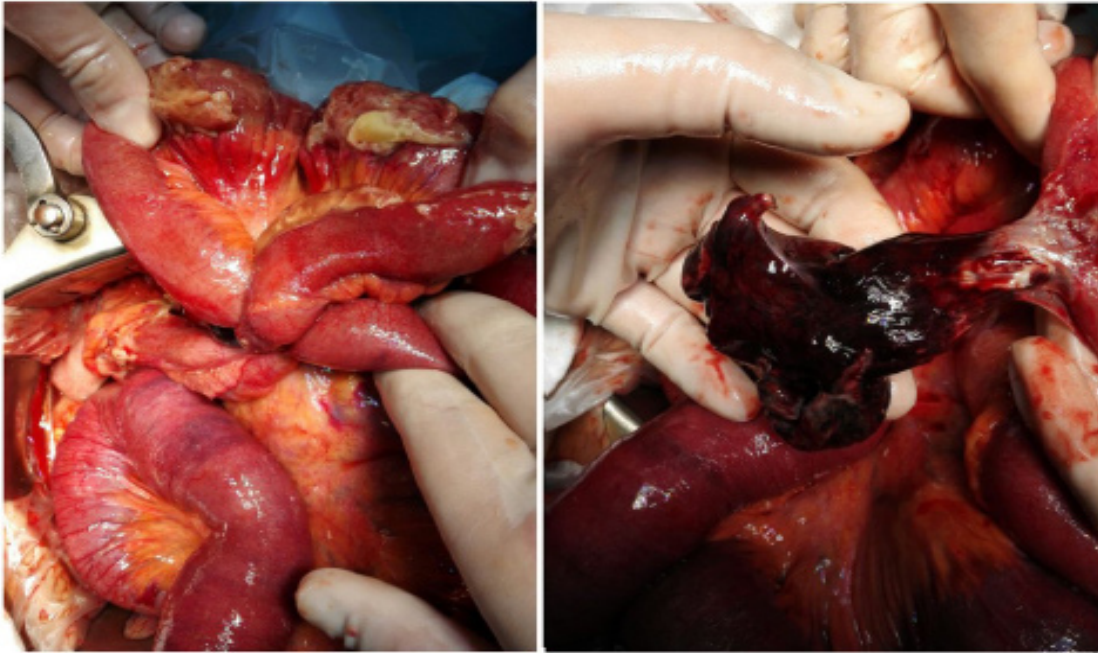


Figure 2: Intraoperative images

References

1. Uggeri F, Pinotti E, Lo Bianco G, Nespoli L, Romano F. Ileal Volvulus Over Cecal Appendix and Meckel's Diverticulum in the Absence of the Mesodiverticular Band: Case Report and Literature Review. *J Clin Gastroenterol Treat.* 2016; 2: 02.
2. Uggeri F, Ronchi PA, Pinotti E, et al. Small Bowel Diverticula: Usefulness of the Computed Tomography in a Non-Specific Clinical Presentation. *J Gastrointest Hepat Surg.* 2017; 1: 1-6.

Manuscript Information: Received: October 18, 2018; Accepted: March 22, 2019; Published: March 29, 2019

Authors Information: Pinotti Enrico*; Romano Fabrizio; Degrate Luca; Uggeri Fabio
University of Milano- Bicocca, San Gerardo Hospital, via Pergolesi 33, 20900 Monza (MB), Italy

Citation: E Pinotti, F Romano, L Degrate, F Uggeri. Ischemia and perforation of Meckel's diverticulum presenting with intestinal obstruction. *Open J Clin Med Case Rep.* 2019; 1525.

Copy right statement: Content published in the journal follows Creative Commons Attribution License (<http://creativecommons.org/licenses/by/4.0>). © Enrico P 2019

About the Journal: Open Journal of Clinical and Medical Case Reports is an international, open access, peer reviewed Journal focusing exclusively on case reports covering all areas of clinical & medical sciences.

Visit the journal website at www.jclinmedcasereports.com

For reprints and other information, contact info@jclinmedcasereports.com