

Chapter 1

The Importance of Multidisciplinary Approach for the Management of Liver Metastases from Urological Cancer

Fabio Uggeri*, Enrico Pinotti, Simone Famularo, Alessandro Giani, Fabrizio Romano and Luca Gianotti

Department of Surgery, San Gerardo Hospital,
University of Milano- Bicocca, Italy

***Corresponding Author:** Fabio Uggeri, Department of Surgery, San Gerardo Hospital, University of Milano- Bicocca, via Pergolesi 33, 20900 Monza (MI), Italy, Tel: +390392333651; Email: fabio.uggeri@unimib.it

First Published **December 26, 2017**

Conflict-of-interest statement: No potential conflicts of interest. No financial support.

Copyright: © 2017 Fabio Uggeri, et al.

This article is distributed under the terms of the Creative Commons Attribution 4.0 International License (<http://creativecommons.org/licenses/by/4.0/>), which permits unrestricted use, distribution, and reproduction in any medium, provided you give appropriate credit to the original author(s) and the source.

Abstract

Urological cancers (neoplasm of kidney, prostate, bladder, urethra, renal pelvis, ureter and testicles) are an emerging disease representing more than 18% of estimated new cancer cases in United States in 2017. Metastases from urological cancers can occur to all organs. In this chapter we will discuss the management of liver metastases from urological cancer. Liver metastases are a sign of widespread disease and they are associated with a poor prognosis. The treatment of liver metastases is often complex and should be personalized for each patient depending on tumor extension, extrahepatic disease and general status of patients. Therapeutic decision should be undertaken by a multidisciplinary team including oncologists, surgeons, radiologists, anesthesiologists and pathologists in order to perform a tailored treatment for each patient.

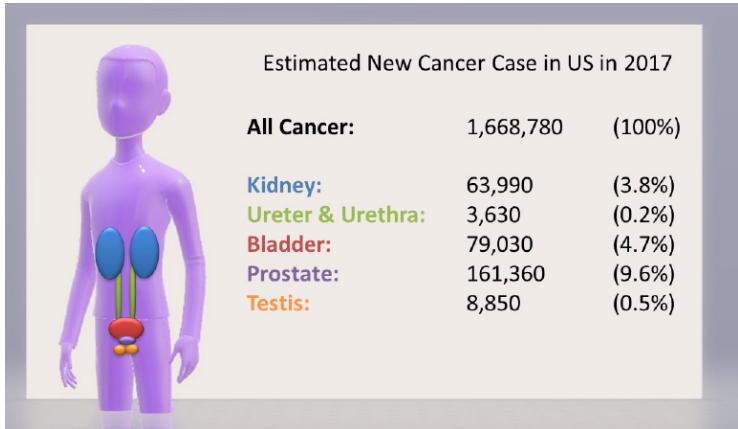
Keywords

Liver metastases; Multidisciplinary Approach; Urological Cancer; Noncolorectal Liver Metastases; Kidney Cancer: Urothelial Cancer; Prostate Cancer; Testis Cancer

Introduction

Urological cancers include neoplasm of kidney, prostate, bladder, urethra, renal pelvis, ureter and testicles. These cancers are relatively common. Prostate cancer, for example, is the most common cancer in men. [1]. Urological cancers represent more than 18% of estimated

new cancer cases in United States, in 2017 (Figure 1) [1]. Metastases from urological cancers can occur hematogenously to all organs, most frequently to the lungs, liver and bone, or lymphatically to regional or retroperitoneal lymph nodes [2]. When metastases are present they are often multiple and associated with extrahepatic disease. In this chapter we will discuss the management of liver metastases from urological cancer. The treatment of liver metastases is often complex and should be personalized for each patient depending on the extension of primitive tumor and metastatic spread. Management of patients should be undertaken by a multidisciplinary team including all the specialties that have a role in the treatment of such patients. A team of surgeon, oncologist, radiologist, anesthesiologist and pathologist should evaluate the best treatment for each of these patients, in order to perform a tailored treatment that could include more than one approach. The clinician can fight these pathologies with various weapons including systemic chemotherapy, radiotherapy, radiological ablation and in selected cases also surgery. The role of surgery for colorectal and neuroendocrine liver metastases is established; while for non-colorectal, nonneuroendocrine liver metastatic disease is less defined, due to scarcity of data and contrasting results [3-4]; for these reasons a multidisciplinary approach becomes necessary for these patients. Many studies have shown that a multidisciplinary approach for patients with primitive or metastatic liver tumors is associated with an increase in patient's survival [5-9].



Liver Metastases from Urological Cancer

Urological cancers include neoplasm of kidney, prostate, bladder, urethra, renal pelvis, ureter and testicles. These organs are very different, each one with specific embryological and genetic characteristics; urological tumors have a different natural history, pathological aggressiveness and therapeutic approaches.

Liver Metastases from Kidney Cancer

The majority of renal cell carcinomas (75-80%) are clear cell subtypes, followed by the papillary (15-20%) and chromophobe tumors (5%) [10]. Liver metastases from kidney cancer represent about 5–10% of noncolorectal nonneuroendocrine liver metastases and are present in

20-40% of metastatic kidney cancers [11,12]. In more than 80% of cases liver metastases from kidney cancer are associated with the presence of a diffuse metastatic spread in other organs (usually lungs or bones) [11], they are usually metachronous (90%) and multiple (75%) [13]. On CT scan liver metastases from kidney cancer are highly vascular, like the primary tumor while in magnetic Resonance are hypointense on the T1-weighted image and iso/hyperintense on the T2-weighted image. Prognosis of these patients is generally poor, with only 10% 1 year overall survival.

Kidney cancer rarely responds to traditional systemic chemotherapy, radiotherapy, or hormone modulation therapy; prognosis of these patients is generally poor and without treatment most patients die within 7 months after diagnosis [14]. For these reasons when is possible the surgical option should be considered, due to the fact that it represent the only potentially curative treatment for these patients. Otherwise only in less than 5% of patients metastases are limited to the liver. About 10% of liver metastases from kidney are synchronous and 90% are metachronous, with 25% of solitary lesions and 75% of multiple nodules. In the multicentric study of Adam et al 85 selected patients underwent surgery for liver metastases from kidney cancer with a median survival of 38 months and a 36% 5-year survival [15]. These data are confirmed in the study of Thelen [16] with a 38.6% of 5 years survival in a 31 re-

sected cases. Other series confirmed a favorable 5 years survival rate ranging from 39% to 60% and the multi-institutional analysis of Hatzaras [17] reported 62.1% 3 years overall survival and 27.3% disease free survival. In their study Hatzaras et al [17] showed that after hepatic resection recurrence occurs in up to 50% of patients, but resection was associated with long-term survival (3-year survival was 62.1%).

In Table 1 are described surgical series for liver metastases from kidney cancer with more than 10 patients. Median Survival ranged from 16 to 142 months and 5-years survival ranged from 8% to 62% [15-23]

Table 1: Outcome after surgery for liver metastases from kidney cancer.

Author	Year	Number of patients	Median Survival (months)	1-year survival (%)	3-year survival (%)	5-year survival (%)
Adam et al. [15]	2006	85	36	-	-	38
Thelen et al [16]	2007	31	48	82	54	39
Hatzaras et al [17]	2012	43	-	94	62	-
Staebler et al [18]	2010	68	142	-	-	62
Ruys et al [19]	2011	33*	33	79	47	43
Marudanayagam et al. [20]	2010	24	22.5	-	-	-
Alves et al [21]	2003	14	26	69	26	-
Lang et al [22]	1999	13	25	-	-	8
Stief et al [23]	1997	13	16	-	-	-

* In this study 29 patients underwent surgical resection and 4 local ablation.

Liver Metastases from Urothelial Cancer

Urothelial tumors are classified as lower urinary tract (bladder and urethra) or upper urinary tract (renal pelvis and ureter). Bladder cancer is the most frequent urothelial tumor (90%) and it is the 7th most common cancer worldwide in men [24]. Shinagare et al showed that liver metastases from urothelial cancer are more frequent in metastatic upper urinary tract tumors (52%) than lower (26%) [25,26]. Inokuchi [27] et al showed a worse overall survival for patient with metastatic upper urinary tract cancer with liver metastasis (6.9 months) when compared with patients without liver involvement (8.8 months). More than 60 % of upper urinary tract cancers are invasive at diagnosis while only 30% of bladder cancers are diagnosed as invasive and metastatic disease [28].

On CT scan, liver metastases from urothelial cancers are typically hypovascular while in magnetic resonance are hyperintense on T2-weighted images.

For metastatic urothelial tumors, chemotherapy, often associated with radiotherapy, represents the standard therapy. Urothelial cancers are chemosensitive and respond to several agents such as Methotrexate, Vinblastine, Doxorubicin, and Cisplatin [29]. The liver is usually one of the many organs involved in the metastatic process, so surgical treatment has been little used for this pathology. In the large analysis of Adam et al [15] on 1452 patients

underwent liver resection for non-colorectal and non-neuroendocrine liver metastases; no one was affected by urothelial cancer.

Liver Metastases from Prostate Cancer

Prostate cancer is the most frequent tumor in man [1]. An estimated 1.1 million cases were diagnosed worldwide each year [30] and it is estimated that there are more than 3.3 million men living with prostate cancer only in the United States [31]. In a large series on 19,316 routine autopsies performed from 1967 to 1995 on men older than 40 years of age, 1,589 (8.2%) patients with prostate cancer were found [32]. Metastatic disease to the bones and lymph nodes has been recognized as the most typical pattern of extraprostatic tumor spread [32]. Liver metastasis from prostate cancer has rarely been reported and remains poorly understood [33]. In the study of Wang et al [34] on 629 patients with metastatic prostate cancer only 27 patients had liver metastases (4.29%) while in the study of Poussel et al [35] only 28 patients on 345 metastatic patients developed liver metastases (8.1%). The real presence of liver metastases may be higher in fact in a large autopsy series on 1,589 patients with hormone refractory prostate cancer Bubendorf [32] reported 35% of metastatic disease and 25% of them had liver metastases. The presence of hepatic metastases reflects a generalized disease; systemic chemotherapy is the standard option for Stage IV prostate

cancer. Chemotherapy has been proven to improve the overall survival of patients with prostate cancer. Surgery is an option for liver metastases from prostate cancer only in selected cases.

Liver Metastases from Testis Cancer

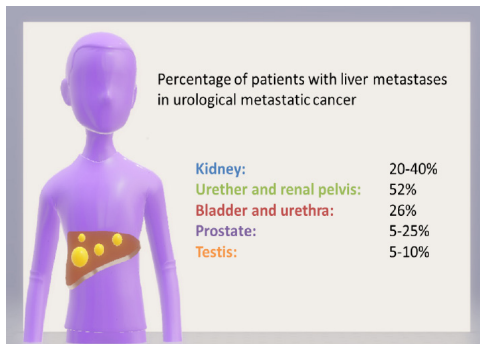
Testis cancer is a rare tumor with an incidence of 8-10,000 new case each year in United States [36]. This neoplasm is frequent in the first several decades of life [36]. Testicular cancer is the most curable solid tumor, with an overall 5-year relative survival rate of 97.3% [37]. Liver metastases from testicular cancer are uncommon. In the series of Copson et al [38] on 1205 patients with germ cell cancer 442 presented with metastatic disease and only 27 were found to have liver metastases at presentation. Metastatic testicular cancer is usually treated with chemotherapy. The most common systemic regimens include combinations of etoposide, cisplatin, bleomycin and ifosfamide [39,40]. Surgery is an option for liver metastases from testicular cancer only in selected cases. In the large analysis of Adam et al [15] patients underwent surgery for liver metastases from testicular cancer showed a long overall survival: 78 patients underwent hepatic resection with a median survival of 82 months and 51% 5-years overall survival. In Table 2 are described surgical series for liver metastases from testicular cancer with more than 20 patients; 5-years survival ranged from 46% to 70% [15,41-43]

Table 2: Outcome after surgery for liver metastases from testis cancer.

Author	Year	Number of patients	Median Survival (months)	1-year survival (%)	3-year survival (%)	5-year survival (%)
Adam et al. [15]	2006	78	82	-	-	51
Hartmann et al [41]	2005	43	-	-	-	70
Elias et al [42]	1998	20	-	68	46	46
Weitz et al [43]	2005	20	-	-	72	-

Multidisciplinary Approach

Urological tumors are very different with a different natural history and the risk of liver metastases depends on the primary tumor (Figure 2). Management of patients with liver metastases from urological cancer should be undertaken by a multidisciplinary team including all the specialties those have a role in the treatment of such patients.



The Role of Oncologist

Urological tumors have a different pathological aggressiveness and chemosensitivity. Liver metastases, when present are often associated with a multi-organ metastatic diffusion and solitary liver metastases are rare. Stage IV metastatic tumor is associated in most of cases with a very bad prognosis. The oncologist plays a major role in the therapeutic decision for these patients; for metastatic tumors chemotherapy is usually the only therapeutic chance to prolong survival. Used drugs are different and depend on the primitive tumor and histologic characteristics.

The Role of Hepatic Surgeon

The role of hepatic surgery for colorectal and neuroendocrine liver metastases is well defined. Conversely, the role of surgery for noncolorectal, nonneuroendocrine, liver metastatic disease is less defined, due to scarcity of data and contrasting results; however some studies have demonstrated good results in selected patients. But in which patients liver surgery should be considered?

In our opinion three factors should be evaluated:

1) Patient must be fit for surgery.

Patients must be medically fit for anesthesia and recovery, the general state of health of the patient and performance status should be evaluated in order to estimate the risk for surgery.

2) Liver function must be adequate.

Hepatic function should always be tested before surgery to detect possible hepatic injury due to neo-adjuvant chemotherapy that may contraindicate major liver resections. Complete hematochemical examinations are mandatory before surgery and in case of further doubts other more specific tests should be performed such as technologies for non-invasive measurement of liver function and splanchnic perfusion monitoring, based on elimination of Indocyanine Green. The future liver remnant should be adequate and if extended hepatectomy is needed preoperative portal vein embolization should be considered.

3) The resection must have an oncological rationale

The decision for surgery is often complex and controversial. The data in the literature are few and there are no guidelines for these pathologies. Many criteria should be evaluated: number and size of lesions, presence of extra-hepatic disease, timing of appearance of liver metastases, response to chemotherapy.

Adam [15] et al proposed a prognostic score to estimate survival after liver resection for non-colorectal, non-neuroendocrine liver metastases (Table 3). Estimated 5-year survival is more than 30% for patients having 0 to 3 points, 10% to 30% for those having 4 to 6 points, and less than 10% for those having more than 6 points.

Table 3: Adam Score.

Presence of extrahepatic metastases	Yes	1
	No	0
R2 Resection	Yes	1
	No	0
Major hepatectomy	Yes	1
	No	0
Age of patient (years)	> 60	2
	30-60	1
	< 30	0
Time between diagnosis of primitive tumor and liver metastases (months)	< 12	2
	12-24	1
	> 24	0
Primary tumour characteristics	Melanoma	3
	Squamous	2
	Other	1
	Breast	0

Similarly other studies showed that factors associated with a worsen prognosis are synchronous, multiple or large liver metastases, R2 resection, major hepatectomy and presence of extrahepatic disease [44-47]. All these factors should be considered in a multidisciplinary meeting for the therapeutic decision; selection of patients for hepatectomy requires a three-part stepwise evaluation including assessment for medical, oncological, and technical resectability. For synchronous liver metastases, resection of liver metastases should always be associated with the resection of the primary tumor. In general surgery should be considered in case of single, small and metachronous liver metastasis, in the absence of extrahepatic disease.

The Role of Anesthesiologist

When liver resection is technically feasible and potentially radical from the oncological point of view the role of the anesthesiologist is crucial. The anesthesiologist should assess the general state of health of the patient and his comorbidities in order to estimate the risk for surgery. Proper balance between risks and benefits is essential prior to invasive surgery and usually anesthesia is the maker of this decision.

The Role of Radiologist

Radiologist plays a key role in the management of patients with liver metastases from urological cancer. It is necessary for the radiologist to describe the number and size of liver metastases, their relationship with vascular liver structures, and the possible presence of extraepathic

disease. Liver metastases radiological study is also necessary for assessment of surgical resectability. At CT scan liver metastases from urological cancer are usually hypovascular but liver metastases from kidney cancer are hypervascular.

The interventionist radiologists may perform percutaneous biopsy under ultrasound or CT guidance or in some cases perform local ablative treatments. Ablative therapies include cryoablation, radiofrequency ablation (RFA) and other local treatment like trans-arterial chemoembolization (TACE). Only few studies on this topic are present in literature; ablative therapies are relatively recent techniques and liver metastases from urological cancer are relatively rare [48-49]

The Role of Pathologist

For non-colorectal non-neuroendocrine liver metastases biopsy is usually not needed. Histologic diagnosis may be necessary in case of liver masses that appeared many years after the removal of primitive tumor, when diagnosis is not radiologically clear, in order to discern between liver metastases and other pathologies for example cholangiocarcinoma or benign diseases.

Conclusion

In conclusion urological tumors are very heterogeneous pathologies. When liver metastases are present they are a sign of widespread disease and are associated with a

poor prognosis. Various weapons can be used for these pathologies including systemic chemotherapy, radiotherapy, radiological ablation and in selected cases also surgery. A multidisciplinary approach to each patient can provide a personalized therapy and achieve a longer survival.

References

1. Siegel RL, Miller KD, Jemal A. Cancer Statistics, 2017. *CA Cancer J Clin.* 2017; 67: 7-30.
2. Shinagare AB, Ramaiya NH, Jagannathan JP, Fennessy FM, Taplin ME, et al. Metastatic pattern of bladder cancer: correlation with the characteristics of the primary tumor. *AJR Am J Roentgenol.* 2011; 196: 117-122.
3. Treska V, Liska V, Skalicky T, Sutnar A, Treskova I, et al. Non-colorectal liver metastases: surgical treatment options. *Hepato-Gastroenterology.* 2012; 59: 245-248.
4. Duan XF, Dong NN, Zhang T, Li Q. Comparison of surgical outcomes in patients with colorectal liver metastases versus non-colorectal liver metastases: a Chinese experience. *Hepatology Research.*
5. Ratti F, Cipriani F, Ferla F, Catena M, Paganelli M, et al. Hilar cholangiocarcinoma: preoperative liver optimization with multidisciplinary approach. Toward a better outcome. *World J Surg.* 2013; 37: 1388-1396.

6. Garancini M, Pinotti E, Nespoli S, Romano F, Gianotti L, et al. Hepatic resection beyond barcelona clinic liver cancer indication: When and how. *World J Hepatol.* 2016; 8: 513-519.
7. Adam R, De Gramont A, Figueras J, Guthrie A, Kokudo N, et al. The oncosurgery approach to managing liver metastases from colorectal cancer: a multidisciplinary international consensus. *Oncologist.* 2012; 17: 1225-1239.
8. Giuliani J, Marzola M. Multidisciplinary approach as the key factor in the management of liver metastases from colorectal cancer. *J Gastrointest Cancer.* 2013; 44: 486-488.
9. Isoniemi H, Osterlund P. Surgery combined with oncological treatments in liver metastases from colorectal cancer. *Scand J Surg.* 2011; 100: 35-41.
10. Chow WH, Dong LM, Devesa SS. Epidemiology and risk factors for kidney cancer. *Nat Rev Urol.* 2010; 7: 245-257.
11. Bianchi M, Sun M, Jeldres C, Shariat SF, Trinh QD, et al. Distribution of metastatic sites in renal cell carcinoma: a population-based analysis. *Ann Oncol.* 2012; 23: 973-980.
12. Ritchie AW, Chisholm GD. The natural history of renal carcinoma. *Semin Oncol.* 1983; 10: 390-400.

13. Janzen NK, Kim HL, Figlin RA, Belldegrun AS. Surveillance after radical or partial nephrectomy for localized renal cell carcinoma and management of recurrent disease. *Urol Clin North Am.* 2003; 30: 843-852.
14. Suppiah R, Shaheen PE, Elson P, Misbah SA, Wood L, et al. Thrombocytosis as a prognostic factor for survival in patients with metastatic renal cell carcinoma. *Cancer.* 2006; 107: 1793-1800.
15. Adam R, Chiche L, Aloia T, Elias D, Salmon R, et al. Hepatic resection for noncolorectal nonendocrine liver metastases: analysis of 1,452 patients and development of a prognostic model. *Ann Surg.* 2006; 244: 524-535.
16. Thelen A, Jonas S, Benckert C, Lopez-Hänninen E, Rudolph B, et al. Liver resection for metastases from renal cell carcinoma. *World J Surg.* 2007; 31: 802-807.
17. Hatzaras I, Gleisner AL, Pulitano C, Sandroussi C, Hirose K, et al. A multi-institution analysis of outcomes of liver-directed surgery for metastatic renal cell cancer. *HPB (Oxford).* 2012; 14: 532-538.
18. Staehler MD, Kruse J, Haseke N, Stadler T, Roosen A, et al. Liver resection for metastatic disease prolongs survival in renal cell carcinoma: 12-year results from a retrospective comparative analysis. *World J Urol.* 2010; 28: 543-547.

19. Ruys AT, Tanis PJ, Nagtegaal ID, van Duijvendijk P, Verhoef C, et al. Surgical treatment of renal cell cancer liver metastases: a population-based study. *Ann Surg Oncol.* 2011; 18: 1932-1938.
20. Marudanayagam R, Sandhu B, Perera MT, Taniere P, Coldham C, et al. Hepatic resection for non-colorectal, non-neuroendocrine, non-sarcoma metastasis: a single-centre experience. *HPB (Oxford).* 2011; 13: 286-292.
21. Alves A, Adam R, Majno P, Delvart V, Azoulay D, et al. Hepatic resection for metastatic renal tumors: is it worthwhile? *Ann Surg Oncol.* 2003; 10: 705-710.
22. Lang H, Nussbaum KT, Weimann A, Raab R. Liver resection for non-colorectal, non-neuroendocrine hepatic metastases. *Chirurg.* 1999; 70: 439-446.
23. Stief CG, Jähne J, Hagemann JH, Kuczyk M, Jonas U. Surgery for metachronous solitary liver metastases of renal cell carcinoma. *J Urol.* 1997; 158: 375-377.
24. Burger M, Catto JW, Dalbagni G, Grossman HB, Herr H, et al. Epidemiology and risk factors of urothelial bladder cancer. *Eur Urol.* 2013; 63: 234-241.
25. Shinagare AB, Ramaiya NH, Jagannathan JP, Fennesy FM, Taplin ME, et al. Metastatic pattern of

- bladder cancer: correlation with the characteristics of the primary tumor. *AJR Am J Roentgenol.* 2011; 196: 117-122.
26. Shinagare AB, Fennessy FM, Ramaiya NH, Jagannathan JP, Taplin ME, et al. Urothelial cancers of the upper urinary tract: metastatic pattern and its correlation with tumor histopathology and location. *J Comput Assist Tomogr.* 2011; 35: 217-222.
 27. Inokuchi J, Naito S, Fujimoto H, Hara T, Sakura M, et al. Impact of multimodal treatment on prognosis for patients with metastatic upper urinary tract urothelial cancer: Subanalysis of the multi-institutional nationwide case series study of the Japanese Urological Association. *Int J Urol.* 2016; 23: 224-230.
 28. Margulis V, Shariat SF, Matin SF, Kamat AM, Zigeuner R, et al. Outcomes of radical nephroureterectomy: a series from the Upper Tract Urothelial Carcinoma collaboration. *Cancer.* 2009; 115: 1224-1233.
 29. Sternberg CN, Yagoda A, Scher HI, Watson RC, Geller N, et al. Methotrexate, vinblastine, doxorubicin, and cisplatin for advanced transitional cell carcinoma of the urothelium. Efficacy and patterns of response and relapse. *Cancer.* 1989; 64: 2448-2458.

30. Ferlay J, Soerjomataram I, Dikshit R, Eser S, Mathers C, et al. Cancer incidence and mortality worldwide: sources, methods and major patterns in GLOBOCAN 2012. *Int J Cancer*. 2015; 136: E359-386.
31. Miller KD, Siegel RL, Lin CC, Mariotto AB, Kramer JL, et al. Cancer treatment and survivorship statistics, 2016. *CA Cancer J Clin*. 2016; 66: 271-289.
32. Bubendorf L, Schöpfer A, Wagner U, Sauter G, Moch H, et al. Metastatic patterns of prostate cancer: an autopsy study of 1,589 patients. *Hum Pathol*. 2000; 31: 578-583.
33. Whitmore WF Jr. Natural history and staging of prostate cancer. *Urol Clin North Am*. 1984; 11: 205-220.
34. Wang H, Li B, Zhang P, Yao Y, Chang J. Clinical characteristics and prognostic factors of prostate cancer with liver metastases. *Tumour Biol*. 2014; 35: 595-601.
35. Pouessel D, Gallet B, Bibeau F, Avancès C, Iborra F, et al. Liver metastases in prostate carcinoma: clinical characteristics and outcome. *BJU Int*. 2007; 99: 807-811.
36. Dearnaley D, Huddart R, Horwich A. Regular review: Managing testicular cancer. *BMJ*. 2001; 322: 1583-1588.

37. Verdecchia A, Francisci S, Brenner H, Gatta G, Micheli A, et al. I; EUROCARE-4 Working Group. Recent cancer survival in Europe: a 2000-02 period analysis of EUROCARE-4 data. *Lancet Oncol.* 2007; 8: 784-796.
38. Copson E, McKendrick J, Hennessey N, Tung K, Mead GZ. Liver metastases in germ cell cancer: defining a role for surgery after chemotherapy. *BJU Int.* 2004; 94: 552-558.
39. Feldman DR, Bosl GJ, Sheinfeld J, Motzer RJ. Medical treatment of advanced testicular cancer. *JAMA.* 2008; 299: 672-684.
40. Shelley MD, Burgon K, Mason MD. Treatment of testicular germ-cell cancer: a cochrane evidence-based systematic review. *Cancer Treat Rev.* 2002; 28: 237-253.
41. Hartmann JT, Rick O, Oechsle K, Kuczyk M, Gauler T, et al. Role of postchemotherapy surgery in the management of patients with liver metastases from germ cell tumors. *Ann Surg.* 2005; 242: 260-266.
42. Elias D, Cavalcanti de Albuquerque A, Eggen-spieler P, Plaud B, Ducreux M, et al. Resection of liver metastases from a noncolorectal primary: indications and results based on 147 monocentric patients. *J Am Coll Surg.* 1998; 187: 487-493.

43. Weitz J, Blumgart LH, Fong Y, Jarnagin WR, D'Angelica M, et al. Partial hepatectomy for metastases from noncolorectal, nonneuroendocrine carcinoma. *Ann Surg.* 2005; 241: 269-276.
44. Uggeri F, Pinotti E, Sandini M, Nespoli L, Gianotti L, et al. Prognostic Factors Affecting Long-Term Survival after Resection for Noncolorectal, Non-neuroendocrine, and Nonsarcoma Liver Metastases. *Gastroenterol Res Pract.* 2017; 2017: 5184146.
45. Hoffmann K, Bulut S, Tekbas A, Hinz U, Büchler MW, et al. Is Hepatic Resection for Non-colorectal, Non-neuroendocrine Liver Metastases Justified? *Ann Surg Oncol.* 2015; 22: S1083-1092.
46. Groeschl RT, Nachmany I, Steel JL, Reddy SK, Glazer ES, et al. Hepatectomy for noncolorectal non-neuroendocrine metastatic cancer: a multi-institutional analysis. *J Am Coll Surg.* 2012; 214: 769-777.
47. Sim DPY, Goh BKP, Lee SY, Chan CY, Tan IBH, et al. Preoperative Prognostic Factors After Liver Resection for Non-Colorectal, Non-Neuroendocrine Liver Metastases and Validation of the Adam Score in an Asian Population. *World J Surg.* 2017.
48. Yun BL, Lee JM, Baek JH, Kim SH, Lee JY, et al. Radiofrequency ablation for treating liver metastases from a non-colorectal origin. *Korean J Radiol.* 2011; 12: 579-587.

49. Nabil M, Gruber T, Yakoub D, Ackermann H, Zangos S, et al. Repetitive transarterial chemoembolization (TACE) of liver metastases from renal cell carcinoma: local control and survival results. *Eur Radiol.* 2008; 18: 1456-1463.