



Ileal Volvulus Over Cecal Appendix and Meckel's Diverticulum in the Absence of the Mesodiverticular Band: Case Report and Literature Review

Fabio Uggeri, Enrico Pinotti*, Giulia Lo Bianco, Luca Nespoli and Fabrizio Romano

Department of Surgery, San Gerardo Hospital, University of Milanom, Bicocca, Italy

*Corresponding author: Enrico Pinotti, Department of Surgery, San Gerardo Hospital, University of Milano, Bicocca, via Pergolesi 33, 20900 Monza (MI), Italy, E-mail: enricopinotti@hotmail.it

Abstract

Meckel's diverticulum has an incidence of 2-4% and is the most common congenital defect of the gastrointestinal tract. It is usually asymptomatic, it may become clinically evident in the presence of complications such as haemorrhage, obstruction or diverticulitis. We here report the case of a young patient of 11 years old with intestinal obstruction caused by a volvulus over a loop formed by the adhesion of Meckel's diverticulum to the cecal appendix. In most cases, the formation of volvulus is associated to the persistence of a fibrous band residual from the vitelline arteries attaching the tip of the diverticulum to the abdominal wall providing the momentum which initiates the volvulus. In our case, the volvulus had formed despite the absence of the mesodiverticular band because of the presence of a most uncommon feature: a loop constituted by the Meckel's diverticulum attached to the cecal appendix by an adhesive inflammatory reaction.

Keywords

Meckel's diverticulum, Ileal diverticulum, Intestinal occlusion, Ileal volvulus

Case Presentation

A 11-year-old boy with no relevant medical history was admitted to our emergency department because of colicky, diffuse abdominal associated to vomiting. He had regular bowel movements and no fever. At physical examination abdominal palpation was painful in the right lower quadrant and in mesogastrium with no rebound tenderness, peristalsis was reduced. Blood chemistries were normal. An abdominal plain X-ray study showed gas distension of some small bowel loops in the central region of the abdomen and some air-fluid levels. The abdominal ultrasound scan was normal except for some distended ileal loops filled with liquid in the lower part of the abdomen. The patient was admitted to our surgical ward for overnight clinical observation. Multiple attempts were made but it was not possible to place nasogastric tube for non-cooperation of the young boy. So we performed repeated clinical evaluations and during the night the patient complained of intermittent pain. On the following morning he had biliary vomiting unresponsive to enema, blood chemistries were unchanged but a second plain abdominal X-ray study showed worsened conditions with the appearance of multiple air fluid levels suggesting a frank intestinal obstruction and warranting emergency surgery (Figure 1).

After adequate antibiotic prophylaxis, we approached the patient through laparoscopy but were forced to convert to laparotomy through a small periumbilical midline incision because of the massive ileal distension and the resulting risk of intestinal perforation. At surgical exploration we found a small quantity of serous free fluid and the presence of a distended Meckel's diverticulum at about 60 cm from then ileal-cecal valve. Both the Meckel's diverticulum and the cecal appendix were involved in an inflammatory adhesive reaction and constituted a loop over which an ileal volvulus had formed (Figure 2).

The adjoining small bowel loops showed no sign of inflammation and appeared to be distended above the site of the volvulus. After freeing from adhesions we performed a diverticular resection with a linear stapler and reinforced the closure with an absorbable 4/0 running suture. We also performed a complimentary appendectomy. After the diverticulum resection the bowel gradually regained its usual size and movements, we observed no further signs of ischemia or inflammation or stenosis, therefore no additional resections were needed. Postoperative course was uneventful, oral food intake was

Background

Meckel's diverticulum is a true diverticulum, containing all layers of the small bowel wall, it has an incidence of 2-4% and is the most common congenital defect of the gastrointestinal tract. It results from an incomplete obliteration of the vitelline duct [1]. It usually appears as a pouch 3 to 6 cm in length, although reported size varies from 1 to 56 cm [2]. It develops from the antimesenteric border of the ileum, 45-90 cm proximal to the ileocecal valve. In 50% cases it can contain ectopic or heterotopic tissue such as heterotopic gastric mucosa, pancreatic, jejunal or duodenal tissue. The embryologic origin of the ectopic tissue within the walls of the diverticulum is unknown; theories include an erroneous association between neural crest and endodermal tissue and the lack restrictive mesodermal effect on the local endoderm within the diverticulum. Meckel's diverticulum is usually asymptomatic, it may become clinically evident in the presence of complications such as haemorrhage (caused by ulceration of the small bowel due to acid secretion by ectopic gastric mucosa within the diverticulum), obstruction or diverticulitis. We here report the case of a patient with an intestinal obstruction caused by a volvulus over a loop formed by the adhesion of meckel's diverticulum to the cecal appendix.

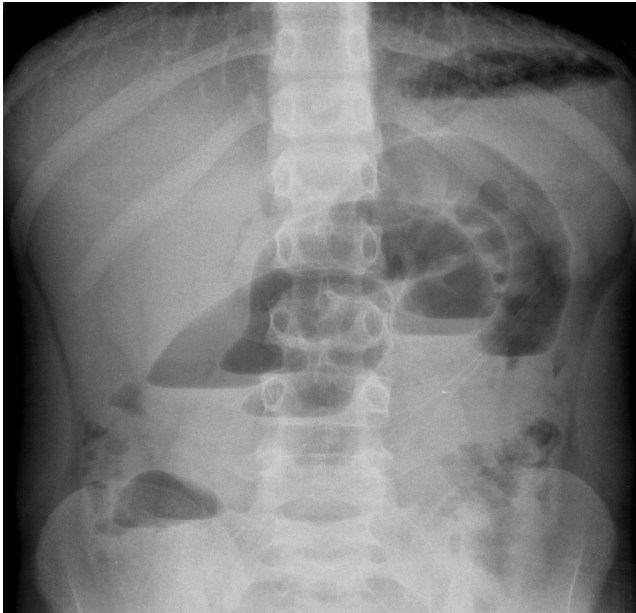


Figure 1: X-ray that shows ileal distension with multiple air fluid levels.

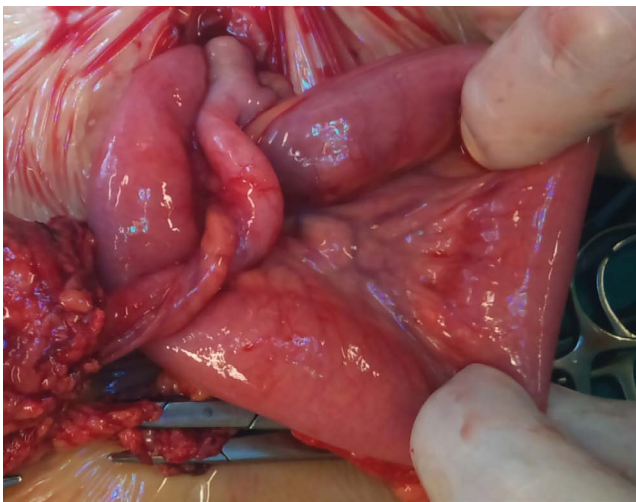


Figure 2: Intraoperative picture of the surgical specimen.

resumed on the second day and regular bowel movements on the fourth. The patient was discharged on the 6th day after surgery. Final histological examination confirmed our diagnosis showing a Meckel's diverticulum composed of three layers and gastric heterotopic mucosa and mucosal cecal appendix with focal mucosal inflammation.

Discussion

Meckel's diverticulum was first described by Fabricius Hildanus in the sixteenth century and later named after Johann Friedrich Meckel who, in 1809, explained its embryological origin [1]. The incidence of Meckel's diverticulum in literature ranges between 0.4 and 6%, but in most cases it remains asymptomatic [2-3]. Meckel's diverticulum may be discovered incidentally during abdominal exploration performed for other presumptive diagnosis. The decision as to whether remove asymptomatic, incidentally discovered Meckel's diverticula is controversial [4,5]. Symptomatic Meckel's diverticula may present with: bleeding, obstruction, ulceration and diverticulitis and, less frequently, perforation, fistula between the diverticulum and the bladder, and malignant degeneration. Typically the vitelline duct obliterates in the embryo between the fifth and ninth week during the progression and rotation of the foregut and hindgut. Contextually the yolk sac also becomes atrophic. The yolk sac is supplied by 2 vitelline arteries, one of them degenerates after the disappearance of the yolk sac while the other evolves into the superior mesenteric artery [6].

If the one of the vitelline arteries fails to degenerate, it transforms into a peritoneum covered fibrous band, or mesodiverticular band, connecting the tip of the Meckel's diverticulum to the ileal wall. This anatomical abnormality has been identified as the cause that initiates volvulus formation in most patients. In patients suffering from complications of a Meckel's diverticulum it is often hard to reach a correct diagnosis [7-10]. In most cases, the formation of volvulus is associated to the persistence of a fibrous band residual from the vitelline arteries attaching the tip of the diverticulum to the abdominal wall providing the momentum which initiates the volvulus. Intestinal occlusion due to volvulus is a very rare presentation of symptomatic Meckel's diverticulum described in few case report [11]. Nowadays laparoscopy is safe and effective in the management of complicated Meckel diverticulum in children. It is useful as both a diagnostic and therapeutic modality [12]. Actually laparoscopy is considered the best surgical approach to intestinal occlusion in children with a conversion rate of 18%-25% and a morbidity rate comparable to open surgery [13,14]. Furthermore laparoscopy can be used in uncertain clinical presentation like diagnostic tool and it can direct to perform a smaller surgical incision in case of conversion [15]. In our case the laparoscopic approach was not diagnostic and the conversion was necessary for the impossibility of having a working space due to the extreme ileal distension. The volvulus had formed despite the absence of the mesodiverticular band because of the presence of a most uncommon feature: a loop constituted by the Meckel's diverticulum attached to the cecal appendix by an adhesive inflammatory reaction.

Conclusion

Intestinal occlusion is a frequent presentation of symptomatic Meckel's diverticulum in childhood. Usually the occlusive framework is due to presence of mesodiverticular band that represents occlusive mechanism. Our case is unusual because the volvulus was made by a torsion between appendix and Meckel's diverticulum in the absence of mesodiverticular band.

Consent

Written informed consent was obtained from the patient for publication of this Case report and any accompanying images.

Competing Interests

No potential conflicts of interest. No financial support.

Author Contributions

All authors equally contributed to this paper. U.F. And P.E. Have devised and wrote the manuscript. L.B.G. helped draft the manuscript. N.L. And R.F. revised critically the manuscript.

Acknowledgements

Greeting to International Center of Digestive Health (School of Medicine and Surgery, University of Milan Bicocca).

References

1. Chaudhuri TK, Christie JH (1972) False positive Meckel's diverticulum scan. *Surgery* 71: 313.
2. Sagar J, Kumar V, Shah DK (2006) Meckel's diverticulum: a systematic review. *J R Soc Med* 99: 501-505.
3. Malik AA, Shams-ul-Bari, Wani KA, Khaja AR (2010) Meckel's diverticulum- Revisited. *Saudi J Gastroenterol* 16: 3-7.
4. Bani-Hani KE, Shatnawi NJ (2004) Meckel's diverticulum: comparison of incidental and symptomatic cases. *World J Surg* 28: 917-920.
5. Peoples JB, Lichtenberger EJ, Dunn MM (1995) Incidental Meckel's diverticulectomy in adults. *Surgery* 118: 649-652.
6. Yoo JH, Cerqueira DS, Rodrigues AJ Jr, Nakagawa RM, Rodrigues CJ (2003) Unusual case of small bowel obstruction: persistence of vitelline artery remnant. *Clin Anat* 16: 173-175.
7. Higaki S, Saito Y, Akazawa A, Okamoto T, Hirano A, et al. (2001) Bleeding Meckel's diverticulum in an adult. *Hepatogastroenterology* 48: 1628-1630.
8. Ueberrueck T, Meyer L, Koch A, Hinkel M, Kube R, et al. (2005) The significance of Meckel's diverticulum in appendicitis--a retrospective analysis of 233 cases. *World J Surg* 29: 455-458.

9. Menezes M, Tareen F, Saeed A, Khan N, Puri P (2008) Symptomatic Meckel's diverticulum in children: a 16-year review. *Pediatr Surg Int* 24: 575-577.
10. Lin S, Suhocki PV, Ludwig KA, Shetzline MA (2002) Gastrointestinal bleeding in adult patients with Meckel's diverticulum: the role of technetium 99m pertechnetate scan. *South Med J* 95: 1338-1341.
11. Yıldız İ, Koca YS, Barut İ. (2016) An unusual case of intraabdominal abscess and acute abdomen caused by axial torsion of a Meckel's diverticulum. *Ann Med Surg (Lond)* 6: 74-76.
12. Alemayehu H, Stringel G, Lo IJ, Golden J, Pandya S, et al. (2014) Laparoscopy and complicated meckel diverticulum in children. *JSLS* 18.
13. Alemayehu H, David B, Desai AA, Iqbal CW, St Peter SD (2015) Laparoscopy for small bowel obstruction in children--an update. *J Laparoendosc Adv Surg Tech A* 25: 73-76.
14. Hosn MA, Lakis M, Faraj W, Khoury G, Diba S (2014) Laparoscopic approach to symptomatic meckel diverticulum in adults. *JSLS* 18.
15. Shalaby RY, Soliman SM, Fawy M, Samaha A (2005) Laparoscopic management of Meckel's diverticulum in children. *J Pediatr Surg* 40: 562-567.