

As tears go by: Baby tears trigger more brain activity than adult tears in nulliparous women

Madelon M.E. Riem^{a,b,c}, Marinus, H. van IJzendoorn^{b,c}, Pietro De Carli^d, Ad J.J.M. Vingerhoets^a,
Marian J. Bakermans-Kranenburg^{b,c}

In press Social Neuroscience

^aDepartment of Medical and Clinical Psychology, Tilburg University, Tilburg, The Netherlands

^bCentre for Child and Family Studies, Leiden University, Leiden, The Netherlands

^cLeiden Institute for Brain and Cognition (LIBC), Leiden University, Leiden, The Netherlands

^dUniversity of Milano-Bicocca, Milano, Italy

Correspondence should be addressed to: Marian J. Bakermans-Kranenburg, Centre for Child and Family Studies, Leiden University, P. O. Box 9555, 2300 RB Leiden, the Netherlands. E-mail: bakermans@fsw.leidenuniv.nl

Abstract

The current fMRI study examines brain activity during the perception of infant and adult tears. Infant tears evoke stronger responses in the visual cortex than adult tears, indicating that infant tears are highly salient. In addition, our study shows that infant tears uniquely activate somatosensory pain regions, which could stimulate actions directed at the elimination of the source of pain. Shedding tears may be a strong means to elicit the parent's sharing of the infant's feelings,, thereby strengthening caregiver-infant bonding and securing infant survival.

Key words: infant tears, crying, somatosensory pain regions, fMRI, caregiver-infant bonding

Introduction

Emotional tears are uniquely human. They play an important role in the communication of distress; however, the function of tears may change during development. In infancy, the effectiveness of crying in attracting adults' attention might be more dependent on the acoustics of crying than on tears or other visual cues of distress (Soltis, 2004). The sound of a crying infant alerts the caregiver when the infant is in need or danger, but it is also perceived as aversive by many parents and it can even trigger child abuse and neglect (Soltis, 2004). Infant tears may be functional in buffering the aversive characteristics of infant crying and promoting an empathic reaction to the child. In contrast to infants, adults cry often softly or without sound and the crying episodes are merely comprised of eyes welling up with tears. Thus, whereas infant tears play a role in the establishment of a bond between caregiver and infant, adult tears –as the main cues of adult sadness-- may be more important in the communication of distress. Crying thus progresses from a predominately acoustic signal in infancy to a more subtle visual signal in adulthood (Rottenberg, & Vingerhoets, 2012).

Functional Magnetic Resonance Imaging (fMRI) may offer more insight into differential perception, functions, and evolutionary roles of infant and adult tears. Previous fMRI research on the perception of others' distress is divided into a subfield that covers neural responses to the acoustics of infant crying (e.g. Riem et al., 2011, Swain, 2011) and a subfield that concerns neural processing of visualized negative adult emotions such as sadness or pain (Fusar-Poli et al., 2009, Lamm, Decety, & Singer, 2011), with no particular attention to the role of tears in the communication of distress. Both subfields point to a role of the insula and anterior cingulate cortex in empathy for distress, but they are otherwise unconnected, and they have both neglected

the processing of tears. The current fMRI study aims to connect these subfields and examines differential neural processing of infant versus adult tears. Since infant tears may play a role in the establishment of a bond with the infant, we hypothesize that infant tears elicit more brain activity in empathy related regions than adult tears.

Method

Participants

Participants were fifty-four female undergraduate students from the Department of Child and Family Studies, Leiden University. All participants were screened for MRI contra-indications, psychiatric or neurological disorders, hearing problems, pregnancy, and alcohol and drug abuse, and did not have children of their own. Three participants were excluded due to excessive head movement and two participants were excluded because of technical or health problems during the session. This resulted in a total sample size of 49 female participants for the current study. The mean age of the participants was 19.58 ($SD = 2.11$). Written informed consent was obtained from all participants. Permission for this study was obtained from the Institute's Ethics Committee and from the Leiden University Medical Centre Ethics Committee.

fMRI paradigm and data analysis

In the MRI scanner, participants were exposed to eight adult photos with tears, eight adult photos without tears, eight infant photos with tears, and eight infant photos without tears. All adults and infants had neutral facial expressions. The adult photos were selected from a larger set of photos that were used in previous studies on the perception of tears (Vingerhoets, van de Ven, & van der Velden, in press). Infant photos were created for the purpose of the current fMRI study. See

supplemental material for more information about the stimuli and Figure S1 for an example infant photo. Each photo was presented four times for 2.6 seconds, in random order. Interstimulus intervals were jittered and calculated using Optseq (<https://surfer.nmr.mgh.harvard.edu/optseq/>). Participants were instructed to attend to the photos. Similar to Montoya et al. (2012), a one-back memory task was included in 15% of the trials to ensure that participants maintained attention during the task. During the one-back memory trial, participants were presented a photo with question marks and were asked to indicate whether the current photo was identical to the photo of the previous trial using a button press with the right hand. The fMRI paradigm was programmed and administered using E-Prime software (version 2.0).

See supplemental material for details about fMRI data acquisition and pre-statistics processing. Data analysis was carried out using FEAT (FMRI Expert Analysis Tool) version 6.00, part of FSL (Smith et al., 2004). In native space, functional activity was examined using general linear model analysis. Each condition (infant tear, infant no tear, adult tear, adult no tear, one-back) was modeled separately as a square-wave function. Each predictor was then convolved with a double gamma hemodynamic response function and its temporal derivative was added to the model, giving five regressors. To examine brain regions involved in the perception of tears we tested the following contrasts: 1) infant tear > infant no tear, 2) adult tear > adult no tear, 3) (infant tear > infant no tear) > (adult tear > adult no tear), and 4) (infant tear > infant no tear) < (adult tear > adult no tear).

The first-level contrast images and the corresponding variance images were transformed to standard space and submitted to second level mixed-effects group whole brain analysis. The group mean was tested using one-sample t-tests on these contrasts. The statistical images were thresholded using clusters determined by $Z > 3.1$ and a cluster corrected significance threshold of

$p < .05$. Region of Interest (ROI) analyses were conducted with a priori specified regions of interest: the insula and the anterior cingulate cortex (ACC), anatomically defined using the Harvard–Oxford cortical atlas (<http://fsl.fmrib.ox.ac.uk/fsl/fslwiki/Atlases>). To investigate regions that were activated during the perception of adult tears *and* during the perception of infant tears, we conducted a conjunction analysis using the `easythresh_conj` command within FSL (<http://www2.warwick.ac.uk/fac/sci/statistics/staff/academic-research/nichols/scripts/fsl>).

Results

In whole brain analysis, the contrast infant tear > infant no tear revealed three large clusters of significant activity with peak voxels located in the lateral occipital cortex, the precentral gyrus, and the postcentral gyrus (see Table S1). Significant activity extended into the occipital pole, occipital fusiform gyrus, middle and inferior frontal gyrus, supramarginal gyrus, middle and inferior temporal gyrus, and precuneus (see Table S2 and Figure 1). During the perception of adults with tears compared to adults without tears there was increased activity in the lateral occipital cortex and occipital pole. Furthermore, the contrast (infant tear > infant no tear) > (adult tear > adult no tear) revealed significantly more reactivity to infant tears in the lateral occipital cortex, precuneus, superior parietal lobule, precentral gyrus, and superior and middle frontal gyrus compared to adult tears (see Figure 1, Table S1 and S2). No significant activity was revealed by the contrast (infant tear > infant no tear) < (adult tear > adult no tear). ROI analyses showed that there was no more activity in the anterior cingulate cortex or insula during the perception of infants with tears compared to infants without tears or adults with tears compared to adults without tears. In order to examine regions that were activated during the

perception of adult tears *and* during the perception of infant tears, we conducted a conjunction analysis. Common activity across both adult and infant tears was found in the lateral occipital cortex and occipital pole (see Figure 1).

Discussion

The current study examined the neural mechanism underlying the perception of infant and adult tears. Common activity across both adult and infant tears was found in the visual cortex. Because of their affective relevance and salience, tears seem to evoke strong responses in the visual cortex, pointing to the important role of tears in the communication of distress (Rottenberg, & Vingerhoets, 2012). However, in contrast with the suggestion that tears play a more important role in communicating distress in adulthood than in infancy (Zeifman & Brown, 2011), infant tears elicited more activity in visual regions than adult tears. Although the acoustics of crying are important for providing information about the health condition of the child and eliciting care (Soltis, 2004), our study indicates that infant crying is not only an acoustic signal, but that visual aspects are also important for the communication of distress. Infant tears appear to be highly salient even compared to adult tears and this salience may facilitate caregiving responses to infant distress.

Compared to adult tears, infant tears elicited more activity in brain regions involved in mentalizing, including the precuneus and the middle frontal gyrus, and in the pre- and postcentral gyrus, regions that are part of the somatosensory cortex. To our surprise, no activity in response to infant or adult tears was found in the insula or anterior cingulate cortex. Previous research indicates that we share the affective components of the other people's emotional distress through vicarious activity of the insula and ACC, which contributes to emotion understanding and

empathy. When we see other adults with *physical* pain, the somatosensory cortex is involved in processing the physical and sensory components of the distress, thereby simulating others' painful bodily experiences and contributing to empathy for physical pain (Keysers, Kaas, Gazzola, 2010). However, the somatosensory cortex only responds to adult pain when there is a clearly localized somatic cause for the pain (Keysers, Kaas, Gazzola, 2010). Interestingly, our study shows that the pre- and postcentral gyrus responds to infant tears even in the absence of a somatic cause for the distress. This may indicate that we actually feel the distress of the crying infant and that infant tears evoke more empathic distress than even a tearful crying adult can trigger.

Some limitations should be noted. First, the sample of the current study consisted of women without children. Therefore, our findings can not be generalized to men or parents. In addition, we did not examine how brain activity during the perception of infant and adult tears relates to behavioral responses to tears. Future studies should examine the relation between brain activity and parental caregiving responses to infant tears and address the question whether infant tears trigger feelings of shared distress and buffer the aversive characteristics of the sound of a crying infant.

In conclusion, our study indicates that infant tears uniquely activate somatosensory pain regions and trigger more brain activity than adult tears. This may indicate that infant tears elicit feelings of shared distress, which could stimulate actions directed at the elimination of the source of pain. Shedding tears may be a strong means to elicit the parent's sharing of the infant's feelings. This may improve the infant's chance of survival because it ameliorates the aversive impact of the cry acoustics and facilitates a sensitive caregiving response to the distressed infant.

Acknowledgments

MJB-K and MHvIJ were supported by research grants from the Netherlands Organization for Scientific Research; the Gravitation program of the Dutch Ministry of Education, Culture, and Science; and the European Research Council (MHvIJ: NWO SPINOZA prize; MJBK: VICI grant no. 453-09-003; AdG 669249). We are grateful to photographer Marco Anelli for allowing us to use his pictures for this study and Kiran Ramlakhan for her contribution to data collection.

References

- Deeley, Q., Daly, E.M., Azuma, R., Surguladze, S. Giampietro, V., Brammer, M.J., . . . Murphy, D.G. (2008). Functional atlas of emotional faces processing from adolescence to middle age. *NeuroImage*, *40*, 389-397.
- Fusar-Poli, P., Placentino, A., Carletti, F., Landi, P., Allen, P., Surguladze, S., . . . Politi, P. (2009). Functional atlas of emotional faces processing: a voxel-based meta-analysis of 105 functional magnetic resonance imaging studies. *Journal of Psychiatry & Neuroscience*, *34*, 418-432.
- Jenkinson, M., Bannister, P., Brady, M., & Smith, S. (2002). Improved optimization for the robust and accurate linear registration and motion correction of brain images. *Neuroimage*, *17*(2), 825-841.
- Keysers, C., H. Kaas, J.H., & Gazzola, V. (2010). Somatosensation in social perception. *Nature Reviews Neuroscience*, *11*, 417-428. doi: 10.1038/nrn2833

- Lamm, C., Decety, J., & Singer, T. (2011). Meta-analytic evidence for common and distinct neural networks associated with directly experienced pain and empathy for pain. *Neuroimage*, *54*, 2492–2502. doi: 10.1016/j.neuroimage.2010.10.014
- Montoya, J.L., Landi, N., Kober, H., Worhunsky, P.D., Rutherford, H.J., . . . Potenza, M.N. (2012) Regional brain responses in nulliparous women to emotional infant stimuli. *PLoS One* *7*, e36270. doi: 10.1371/journal.pone.0036270
- Riem, M.M.E., Bakermans-Kranenburg, M.J., Pieper, S., Tops, M., Boksem, M.A.S., Vermeiren, R.R.J.M., . . . Rombouts, S.A.R.B. (2011). Oxytocin modulates amygdala, insula, and inferior frontal gyrus responses to infant crying: A randomized controlled trial. *Biological Psychiatry*, *70*, 291-297. doi: 10.1016/j.biopsych.2011.02.006
- Rottenberg, J. & Vingerhoets, A.J.J.M. (2012). Crying: Call for a lifespan approach. *Social and Personality Psychology Compass*, *6*, 217-227. doi: 10.1111/j.1751-9004.2012.00426.x
- Soltis, J. (2004). The signal functions of early infant crying. *Behavioral and Brain Sciences*, *27*, 443-490.
- Swain, J. (2011). The human parental brain: In vivo neuroimaging. *Progress in Neuro-Psychopharmacology & Biological Psychiatry*, *35*, 1242–1254. doi: 10.1016/j.pnpbp.2010.10.017
- Smith, S.M., Jenkinson, M., Woolrich, M.W., Beckmann, C.F., Behrens, T.E., Johansen-Berg, H., . . . Matthews, P.M. (2004). Advances in functional and structural MR image analysis and implementation as FSL. *Neuroimage*, *23*, S208-219.
- Smith, S.M. (2002). Fast robust automated brain extraction. *Human Brain Mapping*, *17*, 143-155.
- Vingerhoets, A.J.J.M., Ven, N. van de, & Velden, Y. van der (in press). The social impact of emotional tears. *Motivation and Emotion*. doi 10.1007/s11031-016-9543-0

Zeifman, D.M. & Brown, S.A. (2011). Age related changes in the signal value of tears.
Evolutionary Psychology, 9, 313-324.

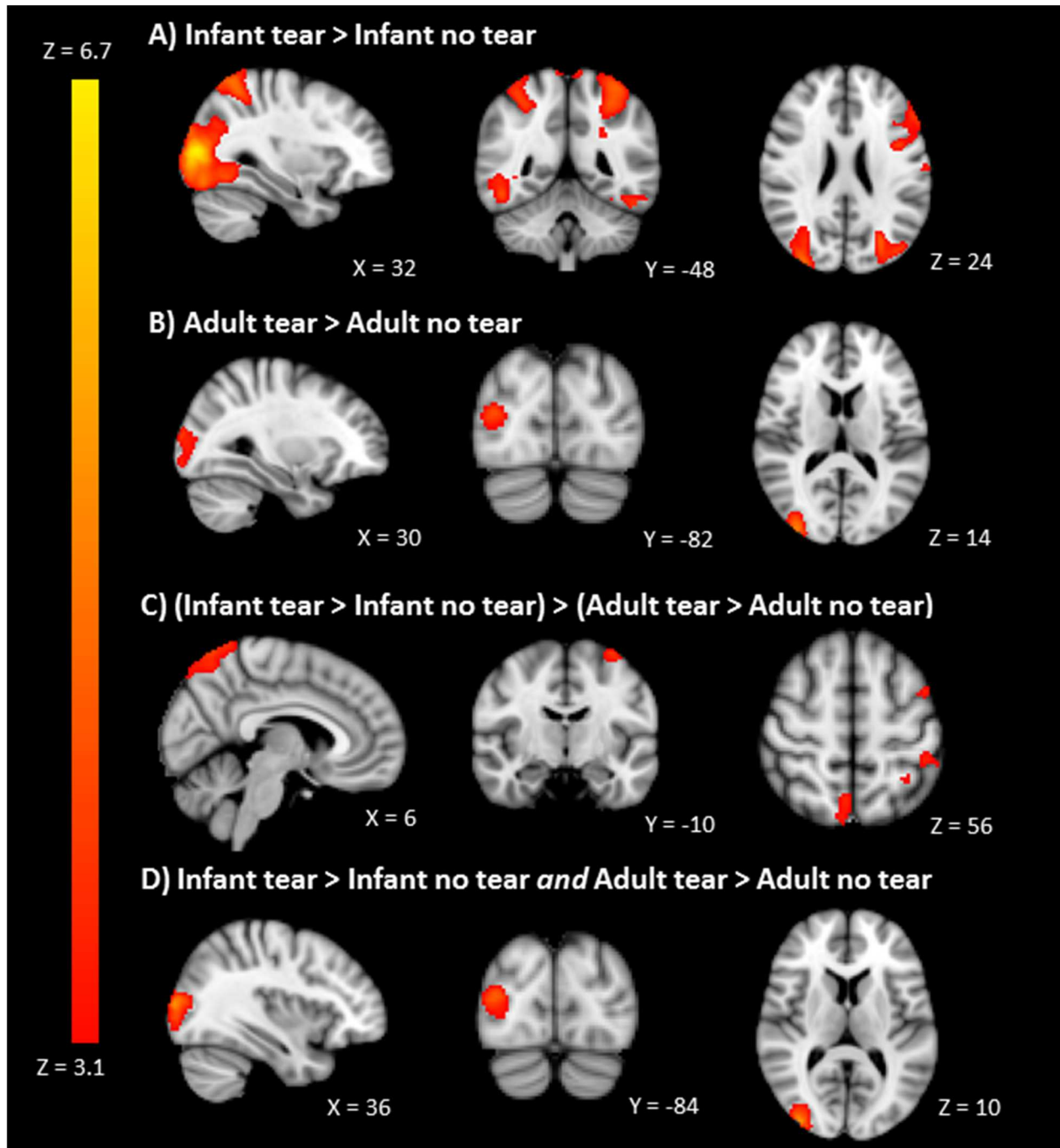


Figure 1.

Significant activity for the contrasts A) Infant tear > Infant no tear, B) Adult tear > Adult no tear, and C) (Infant tear > Infant no tear) > (Adult tear > Adult no tear), and D) results of the

conjunction of Infant tear > Infant no tear *and* Adult tear > Adult no tear, thresholded with clusters determined by $Z > 3.1$ and a cluster-corrected significance threshold of $p < .05$.