

Research Article

Microsurgical Testicular Sperm Extraction: Predictive Factors and Outcomes for Men with Nonobstructive Azoospermia

B. Mahdy ^{1,2}, G. La Croce ¹, M. Roscigno ¹, M. Manica ¹, L. Da Pozzo ^{1,3} and A. Sacca ¹

¹Department of Urology, ASST Papa Giovanni XXIII, Bergamo, Italy

²Faculty of Medicine, Luxor University, Luxor, Egypt

³Faculty of Medicine, University of Milano Bicocca, Milan, Italy

Correspondence should be addressed to B. Mahdy; basyouny.mahdy@medicine.luxor.edu.eg

Received 22 July 2023; Revised 5 December 2023; Accepted 9 January 2024; Published 22 February 2024

Academic Editor: Raul Sanchez

Copyright © 2024 B. Mahdy et al. This is an open access article distributed under the Creative Commons Attribution License, which permits unrestricted use, distribution, and reproduction in any medium, provided the original work is properly cited.

Background. Nonobstructive azoospermia (NOA) is a frequent cause of male infertility, and microsurgical testicular sperm extraction (micro-TESE) is an effective technique for sperm retrieval in NOA cases. However, the predictive factors for successful sperm retrieval and the outcomes of micro-TESE in NOA patients are not fully understood. **Methods.** In this retrospective study, we evaluated the predictive value of preoperative data and outcomes of micro-TESE in 172 men with NOA who underwent the procedure between April 2012 and February 2021. Patients' age, medical history, testicular size, hormonal profile, testicular histology, and sperm retrieval were recorded. **Results.** 172 cases of micro-TESE were performed (99 unilateral and 73 bilateral) and testicular sperm retrieval rate (SRR) was 72.7%. There was no statistical difference in age, testicular size, and hormonal profiles between positive SRR and negative SRR groups. Clinical varicocele and previous orchitis did not significantly affect the result of micro-TESE. Y chromosome microdeletions were detected in seven patients. On histological examination, hypospermatogenesis was found in 39% of patients who underwent testicular biopsy. SRR was higher in patients with hypospermatogenesis than in other groups. **Conclusions.** Testicular microdissection is an effective and safe procedure for nonobstructive azoospermia patients, regardless of the different etiologies and preoperative data. Age, testicular size, and hormonal levels did not predict the success of micro-TESE. The presence of hypospermatogenesis was associated with a higher SRR. Clinical varicocele and previous orchitis were not significantly associated with the outcome of micro-TESE.

1. Background

Nonobstructive azoospermia (NOA) is a challenging form of male infertility that occurs when the testes fail to produce sperm. NOA accounts for up to 20% of infertile men and its treatment often requires the use of assisted reproductive techniques such as intracytoplasmic sperm injection (ICSI) or donor sperm [1, 2].

Microsurgical testicular sperm extraction (micro-TESE) is nowadays the more advanced surgical technique of testicular sperm extraction (TESE) that involves the use of high-powered microscopes to better identify whitish tissue where sperms can be detected [3]. Micro-TESE has been shown to be effective for sperm retrieval in NOA cases, with reported sperm retrieval rates (SRRs), ranging from 30% to 70% [4]. However, the positive predictive factors for successful sperm

retrieval and the outcomes of micro-TESE in NOA patients are still unclear.

Age, testicular size, and preoperative hormonal levels have been suggested to be predictive of the success of micro-TESE in some studies, while others have reported conflicting results [5, 6]. The different etiologies of NOA, such as hypospermatogenesis, sertoli cell-only (SCO) syndrome, and germ cell maturation arrest, may also impact the success of micro-TESE [7]. The presence of clinical varicocele or previous orchitis may also affect the outcome of micro-TESE [8, 9].

Therefore, it is important to evaluate the predictive factors and outcomes of micro-TESE in NOA patients in order to avoid useless procedures. Understanding the factors that influence the success of micro-TESE can improve patient counseling and help guide the selection of the most appropriate treatment option for men with NOA.

TABLE 1: Difference of preoperative characteristics between the positive and negative micro-TESE group.

Preoperative data	Positive micro-TESE N = 125	Negative micro-TESE N = 47	p-Value
Age (years)	37.9 ± 6.29	36.87 ± 6.28	0.882
Right testis volume (mL)	8.32 ± 3.09	8.13 ± 3.12	0.648
Left testis volume (mL)	6.99 ± 3.08	6.63 ± 3.12	0.617
FSH (IU/L)	12.41 ± 11.52	26.01 ± 16.62	0.253
LH (IU/L)	5.82 ± 4.57	9.54 ± 6.64	0.283
PRL (mIU/L)	10.03 ± 4.59	11.8 ± 4.5	0.411
Total testosterone (nmol/L)	5.56 ± 2.9	3.77 ± 2.6	0.369

TABLE 2: Difference of histopathological findings between the positive and negative micro-TESE group.

Histopathological findings	Positive micro-TESE N = 125	Negative micro-TESE N = 47
Parenchymal atrophy	20	18
Sertoli cell-only	14	21
Maturation arrest	24	8
Hypospermatogenesis	67	0

2. Materials and Methods

2.1. *Patient Selection.* We retrospectively collected data of 172 male adult patients (mean 37.49 ± SD 6.37) with NOA who were referred to the male infertility outpatient clinic at our nonacademic community hospital and underwent micro-TESE between April 2012 and February 2021.

Patients’ age; medical history; testicular size; hormone profile for follicle-stimulating hormone (FSH), luteinizing hormone (LH), prolactin, and total testosterone (TT); testicular pathology; and sperm retrieval were obtained from prospective medical records.

Patients with obstructive azoospermia or other causes of male infertility and patients with a history of testicular cancer or who received chemotherapy or radiation therapy within the past 6 months were excluded from the study.

2.2. *Surgical Technique.* All patients underwent the same surgical technique by an experienced male fertility surgeon. The surgical intervention was performed in 1-day surgery clinic under spinal anesthesia. A prophylactic antibiotic treatment was given and 1 week later the patients were all rechecked at outpatient clinic. Surgery was performed unilaterally on the larger testis, and when the testes volume was equal, the procedure was always performed on the right side. Briefly, the tunica vaginalis was opened following a midline scrotal incision. The testis was opened widely in an equatorial plane, revealing the testicular tissue. As a result, seminiferous tubules could be exposed widely in a natural manner that mimics intratesticular blood flow. The remaining steps of the operation were carried out under a 16–25x operating microscope. The tubules were dissected and the tissue samples were collected in separate containers filled with culture medium for immediate examination by an embryologist. Sperm are more likely to be found in tubules that are bigger and more whitish. Depending on the size of the testicles and the condition of the tubules, up to 15 biopsies may be collected. The procedure was repeated on the contralateral testis

if no sperms were found in the first testis. Once all visible parenchymal regions were examined under a microscope or when additional dissection was deemed likely to endanger the testicular blood supply, the surgery was over. The micro-TESE procedure was considered successful if at least one motile spermatozoon was retrieved. An additional sample was collected for the histological examination, which was taken and fixed in Bouin’s solution.

2.3. *Data Collection and Analysis.* Data were collected and analyzed using Statistical Package for Social Sciences (SPSS) version 25. Descriptive statistics were used to summarize the patient demographics, medical history, hormonal profile, testicular histology, and SRR. Continuous variables were reported as mean ± standard deviation (SD), and categorical variables were reported as frequencies and percentages. The independent *t*-test was used to compare continuous variables between the micro-TESE successful and unsuccessful groups. A *p* value of <0.05 was considered statistically significant.

3. Results

We performed 99 (57.6%) cases of unilateral micro-TESE, 84 (48.9%) cases on the right side and 15 (8.7%) cases on the left side. The remaining 73 cases (42.4%) were bilateral. Our testicular SRR was 72.7%.

There were no statistically significant differences in age, testicular size, and hormone levels in the micro-TESE positive and negative groups (Table 1). Hypospermatogenesis was found in testicular histopathology in 67 of 172 patients (39%) who underwent testicular biopsy. SCO syndrome was seen in 20.3%, germ cell maturation arrest (MA) in 18.6%, and atrophy–hyalinization in 22.1%. It was noticed that SRR was higher in patients with hypospermatogenesis than those with other histopathologies (Table 2 and Figure 1).

Clinical varicocele was present in 24 patients at the time of examination, and 21 patients had a history of previous orchitis before undergoing micro-TESE. However, these factors did

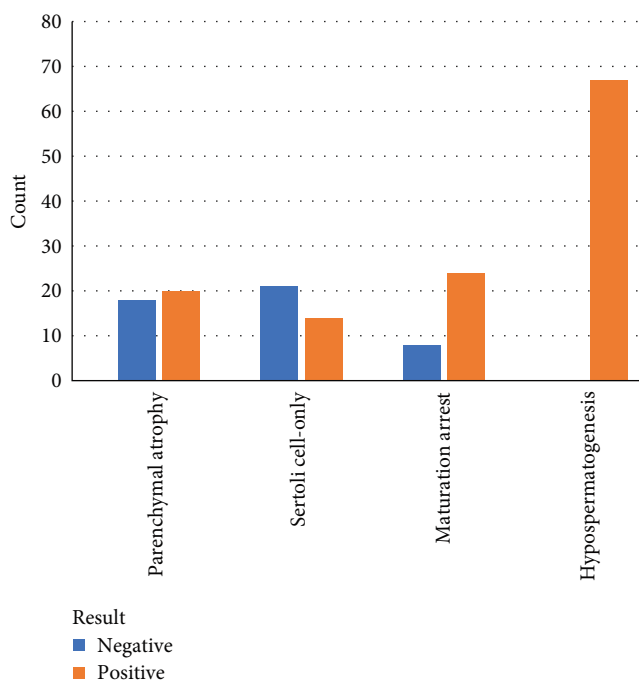


FIGURE 1: Histopathological findings after micro-TESE.

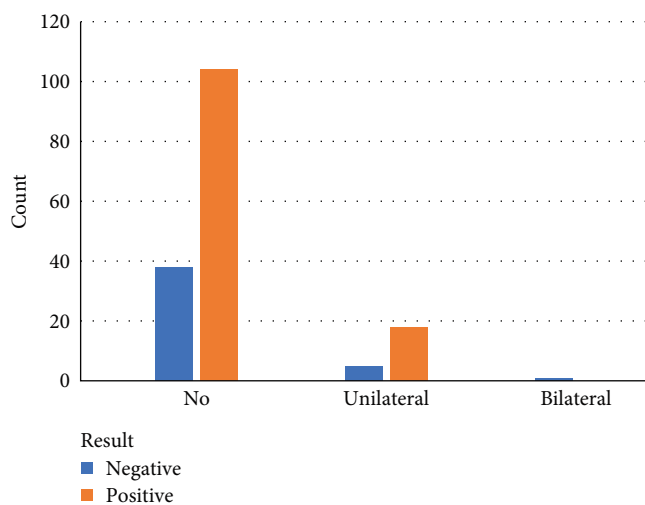


FIGURE 2: Patients with clinical varicocele.

not have a significant effect on the results of micro-TESE (*p* value 0.861 and 0.479, respectively). (Figures 2 and 3).

There were seven patients with Y chromosome microdeletions, one patient had a deletion in the AZFa region, one patient had a deletion in the AZFb region, and five patients had deletions in the AZFc region. Only three of these patients with Y chromosome microdeletions had positive micro-TESE outcomes, and all three had deletions in the AZFc region.

4. Discussion

Micro-TESE is a highly effective technique for retrieving sperms in NOA patients who desire fatherhood. In our study,

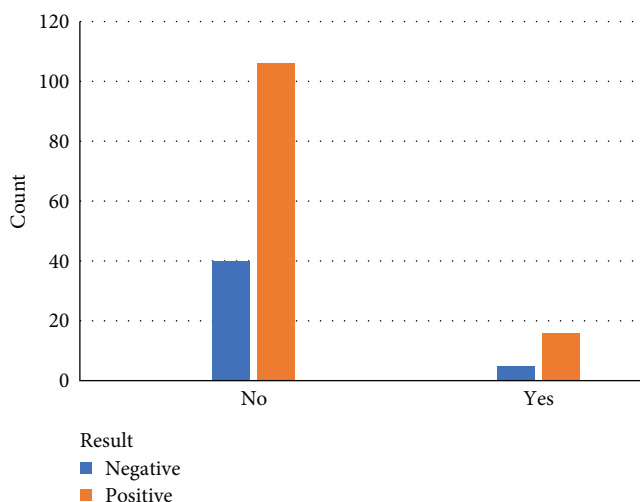


FIGURE 3: Patients with previous orchitis.

we found a testicular SRR of 72.7%, which is similar to what is reported in other studies [10]. The relatively high SRR in our study may be attributed to the meticulous microsurgical dissection of the testicular tissue, which allowed for the identification and extraction of small foci of sperm production.

While age, testicular size, and hormonal levels have been debated as predictors of micro-TESE success [11, 12], our study revealed that there were no statistically significant differences in age, testicular size, and hormone levels between the micro-TESE positive and negative groups. This finding suggests that micro-TESE may be a viable option for men with NOA regardless of their age or hormonal status.

Histopathological examination of the testicular tissue revealed that hypospermatogenesis was the most common histopathology, followed by SCO syndrome, germ cell MA, and atrophy–hyalinization. This finding is consistent with previous reports, which have shown that hypospermatogenesis is the most common cause of NOA [13–15]. Interestingly, we found that SRR was higher in patients with hypospermatogenesis than in those with other histopathologies. This may be due to the fact that hypospermatogenesis involves partial MA of germ cells, which means that there are still some foci of active sperm production that can be identified and extracted by micro-TESE.

Clinical varicocele and previous orchitis have been suggested to negatively impact the results of micro-TESE by causing testicular damage and impairing spermatogenesis. However, in our study, we found that these factors did not impact the results of micro-TESE. This finding is consistent with previous reports that have shown that varicocele repair or a history of orchitis does not necessarily improve the results of micro-TESE [16, 17].

Finally, seven out of the 172 patients were found to have Y chromosome microdeletions. Interestingly, only three of these patients with Y chromosome microdeletions had positive micro-TESE outcomes, and all three had deletions in the AZFc region. The small number of patients with Y chromosome microdeletions limits the generalizability of these findings, but it suggests that the AZFc region may be more

important for spermatogenesis than the AZFa and AZFb regions. Further studies with larger sample sizes are needed to confirm these findings.

Although the study did not produce any unexpected results, the higher SRR in patients with hypospermatogenesis suggests that testicular histopathology may be a useful predictor of the success of micro-TESE. Further research is needed to investigate the potential role of hormonal therapy in improving the success of micro-TESE in patients with NOA. One limitation of this study is its retrospective design, which may have limited the quality and completeness of the data collected. Future studies should investigate the relationship between histopathology findings and SRR in larger samples and across different patient populations. Finally, the study did not investigate the long-term outcomes of micro-TESE, such as pregnancy rates and live birth rates, which may be important measures of the procedure's overall effectiveness.

5. Conclusions

Testicular microdissection is an effective and safe procedure for cases of NOA despite the different etiologies and preoperative characters.

Abbreviations

NOA:	Nonobstructive azoospermia
TESE:	Testicular sperm extraction
micro-TESE:	Microsurgical testicular sperm extraction
SRR:	Sperm retrieval rate
ICSI:	Intracytoplasmic sperm injection
FSH:	Follicle-stimulating hormone
LH:	Luteinizing hormone
TT:	Total testosterone
SCO:	Sertoli cell-only syndrome
MA:	Germ cell maturation arrest.

Data Availability

The data used to support the findings of this study are available from the corresponding author upon request.

Conflicts of Interest

The authors declare that they have no conflicts of interest.

References

- [1] S. C. Esteves, R. Miyaoka, and A. Agarwal, "An update on the clinical assessment of the infertile male," *Clinics*, vol. 66, no. 4, pp. 691–700, 2011.
- [2] A. Jungwirth, A. Giwercman, H. Tournaye et al., "European Association Of Urology Guidelines on male infertility: the 2012 update," *European Urology*, vol. 62, no. 2, pp. 324–332, 2012.
- [3] P. N. Schlegel, "Testicular sperm extraction: microdissection improves sperm yield with minimal tissue excision," *Human Reproduction*, vol. 14, no. 1, pp. 131–135, 1999.
- [4] A. Tsujimura, K. Matsumiya, Y. Miyagawa et al., "Conventional multiple or microdissection testicular sperm extraction: a comparative study," *Human Reproduction*, vol. 17, no. 11, pp. 2924–2929, 2002.
- [5] T. Xu, L. Peng, X. Lin, J. Li, and W. Xu, "Predictors for successful sperm retrieval of salvage microdissection testicular sperm extraction (TESE) following failed TESE in non-obstructive azoospermia patients," *Andrologia*, vol. 49, no. 4, Article ID e12642, 2017.
- [6] R. Ramasamy, K. Lin, L. V. Gosden, Z. Rosenwaks, G. D. Palermo, and P. N. Schlegel, "High serum FSH levels in men with nonobstructive azoospermia does not affect success of microdissection testicular sperm extraction," *Fertility and Sterility*, vol. 92, no. 2, pp. 590–593, 2009.
- [7] F. Tüttelmann, F. Werny, T. G. Cooper, S. Kliesch, M. Simoni, and E. Nieschlag, "Clinical experience with azoospermia: aetiology and chances for spermatozoa detection upon biopsy," *International Journal of Andrology*, vol. 34, no. 4pt1, pp. 291–298, 2011.
- [8] S. Verza Jr and S. C. Esteves, "Sperm defect severity rather than sperm source is associated with lower fertilization rates after intracytoplasmic sperm injection," *International Braz J Urol*, vol. 34, no. 1, pp. 49–56, 2008.
- [9] M. Wosnitzer, M. Goldstein, and M. P. Hardy, "Review of azoospermia," *Spermatogenesis*, vol. 4, no. 1, Article ID e28218, 2014.
- [10] A. Tsujimura, K. Matsumiya, Y. Miyagawa et al., "Prediction of successful outcome of microdissection testicular sperm extraction in men with idiopathic nonobstructive azoospermia," *Journal of Urology*, vol. 172, no. 5, pp. 1944–1947, 2004.
- [11] A. Tsujimura, Y. Miyagawa, T. Takao et al., "Salvage microdissection testicular sperm extraction after failed conventional testicular sperm extraction in patients with nonobstructive azoospermia," *Journal of Urology*, vol. 175, no. 4, pp. 1446–1449, 2006.
- [12] R. Ramasamy, W. O. Padilla, E. C. Osterberg et al., "A comparison of models for predicting sperm retrieval before microdissection testicular sperm extraction in men with nonobstructive azoospermia," *Journal of Urology*, vol. 189, no. 2, pp. 638–642, 2013.
- [13] S. J. Silber, A. Van Steirteghem, Z. Nagy, J. Liu, H. Tournaye, and P. Devroey, "Normal pregnancies resulting from testicular sperm extraction and intracytoplasmic sperm injection for azoospermia due to maturation arrest," *Fertility and Sterility*, vol. 66, no. 1, pp. 110–117, 1996.
- [14] S. C. Esteves, R. Miyaoka, J. E. Orosz, and A. Agarwal, "An update on sperm retrieval techniques for azoospermic males," *Clinics*, vol. 68, pp. 99–110, 2013.
- [15] J. L. Pryor, M. Kent-First, A. Muallem et al., "Microdeletions in the Y Chromosome of infertile men," *New England Journal of Medicine*, vol. 336, no. 8, pp. 534–540, 1997.
- [16] T. Ishikawa, Y. Kondo, K. Yamaguchi, Y. Sakamoto, and M. Fujisawa, "Effect of varicocelelectomy on patients with unobstructive azoospermia and severe oligospermia," *BJU International*, vol. 101, no. 2, pp. 216–218, 2008.
- [17] A. Tsujimura, Y. Miyagawa, K. Fujita et al., "1408: salvage microdissection testicular sperm extraction after failed conventional tesse for patients with non-obstructive azoospermia," *Journal of Urology*, vol. 175, no. 4S, Article ID 454, 2006.