



## Dermatology Reports

<https://www.pagepress.org/journals/index.php/dr/index>

eISSN 2036-7406



**SIDCO**

Società Italiana di Dermatologia  
Chirurgica, Oncologica, Correttiva ed Estetica

**Publisher's Disclaimer.** E-publishing ahead of print is increasingly important for the rapid dissemination of science. **Dermatology Reports** is, therefore, E-publishing PDF files of an early version of manuscripts that undergone a regular peer review and have been accepted for publication, but have not been through the copyediting, typesetting, pagination and proofreading processes, which may lead to differences between this version and the final one.

The final version of the manuscript will then appear on a regular issue of the journal. E-publishing of this PDF file has been approved by the authors.

*Please cite this article as: Buffon S, Parietti M, Carugno A, et al. Metronidazole-induced linear immunoglobulin A disease in a patient suffering from ulcerative colitis: a case report and focused review of the literature. Dermatol Rep 2023 [Epub Ahead of Print] doi: 10.4081/dr.2023.9831*



© the Author(s), 2023  
Licensee PAGEPress, Italy

Note: The publisher is not responsible for the content or functionality of any supporting information supplied by the authors. Any queries should be directed to the corresponding author for the article.

All claims expressed in this article are solely those of the authors and do not necessarily represent those of their affiliated organizations, or those of the publisher, the editors and the reviewers. Any product that may be evaluated in this article or claim that may be made by its manufacturer is not guaranteed or endorsed by the publisher.

# **Metronidazole-induced linear immunoglobulin A disease in a patient suffering from ulcerative colitis: a case report and focused review of the literature**

S. Buffon<sup>1</sup>, M. Parietti<sup>2</sup>, A. Carugno<sup>2,3</sup>, E. Robustelli Test<sup>2</sup>, A.V. Marzano<sup>1,4</sup>, P. Sena<sup>2</sup>, P. Vezzoli<sup>2</sup>

1. Dermatology Unit, Foundation IRCCS Ca' Granda Ospedale Maggiore Policlinico, University of Milan, Italy.
2. Dermatology Unit, ASST Papa Giovanni XXIII Hospital, Bergamo, Italy.
3. Ph.D. Program in Molecular and Translational Medicine (DIMET), University of Milan-Bicocca, Milan, Italy
4. Department of Pathophysiology and Transplantation, University of Milan, Italy.

Conflicts of interest and source of funding: none declared.

Corresponding author: Michele Parietti  
Dermatology Unit ASST Papa Giovanni XXIII Hospital,  
Piazza OMS 1, Bergamo, Italy  
Phone number: +39 035 2678484  
mparietti@asst-pg23.it

Key words: autoimmune blistering disease, drug induced dermatosis.

Acknowledgement: The patients in this manuscript have given written informed consent to the publication of their case details.

Data available upon request to corresponding author.

## **Abstract**

Linear immunoglobulin (Ig) A disease (LAD) is a rare autoimmune blistering dermatosis caused by linear deposition of IgA1 along the dermoepidermal junction of skin and mucosae. It can affect both children and adults. Although idiopathic in most cases, it can also be associated with infections, malignancies, or drug administration. Among medications, antibiotics are most commonly responsible, particularly vancomycin. We report the case of a 51-year-old female patient who developed mucocutaneous LAD after oral metronidazole administration, which was confirmed by histopathological examination and direct immunofluorescence of one of the bullous lesions. Lesions rapidly cleared after metronidazole discontinuation and a short course of oral methylprednisolone and dapsone. To our knowledge, this is the third reported case of metronidazole-induced LAD, and the first in which metronidazole was not administered in combination with other antibiotics such as ceftriaxone.

## **Introduction**

Linear immunoglobulin (Ig) A disease (LAD) is a rare autoimmune mucocutaneous blistering dermatosis characterized by the linear deposition of IgA along the dermoepidermal junction. Its incidence is estimated to be less than 2.3 cases per million individuals per year, with no predilection in terms of sex or ethnicity. Although it is idiopathic in most cases, LAD can rarely be drug-induced or associated with infections or internal malignancies.<sup>1</sup> Antibiotics, especially vancomycin, are the most often involved drugs.<sup>2</sup> LAD can arise both in childhood – an entity previously known as chronic bullous disease of childhood – and in adulthood. The childhood-onset form usually develops after 6 months and before 5-6 years, usually resolving at puberty, while the adult form generally appears after the seventh decade.<sup>3</sup> The clinical presentation consists of subepidermal vesicles or bullae with a tense consistency, often with an annular or arciform distribution, sometimes mimicking dermatitis herpetiformis (DH), bullous pemphigoid (BP), or toxic epidermal necrolysis (TEN). Mucosal erosions and ulcers are frequent.<sup>4</sup> First-line therapy includes dapsone and topical corticosteroids, while refractory cases require other sulfonamides, colchicine, or systemic immunosuppressants.<sup>1</sup>

## **Case report**

A 51-year-old woman was referred to our unit in early May 2017 due to a moderately pruritic generalized dermatosis which had abruptly arisen about 1 month earlier. She suffered from ulcerative colitis (UC) since 2014 and had been treated with mesalazine for 1 year. About 2 weeks before the dermatosis onset, she had begun an antibiotic course with oral metronidazole 500 mg every 8 hours due to a UC flare-up with suspicion of superinfection. On first examination, she presented multiple round erythematous-edematous plaques and vesiculobullous lesions involving her axillae, trunk, genitals, buttocks, and extensor aspect of her lower limbs with a symmetric distribution. The vesiculobullous lesions appeared tense and had developed on both inflamed and non-inflamed skin. Some were isolated, while others were either clustered or grouped in an annular fashion with a 'string of pearls' aspect. Erosions and partially crusted lesions were visible as well. The oral mucosa was also involved with vesicles and erosions on the hard palate. In the suspicion of BP or LAD, the patient underwent a skin biopsy. Histological examination on hematoxylin-eosin staining revealed a subepidermal blister with an underlying inflammatory infiltrate dominated by neutrophils and occasional eosinophils. Direct immunofluorescence highlighted a linear IgA deposition along the dermoepidermal junction, with a 'roof pattern' (i.e., antibody deposition on the epidermal side of the blister) on 1 M NaCl-split skin. ELISA test did not detect any circulating antibodies against basement membrane zone (BMZ) components. Therefore, taking clinical and histological data into account, a diagnosis of mucocutaneous LAD was made. Considering the short interval between antibiotic administration and dermatosis onset, suspecting a possible drug-induced LAD, oral metronidazole was suspended. The patient started a treatment course with oral methylprednisolone 16 mg/d with subsequent tapering over 20 days and oral dapsone 50 mg/d.

Within 1 month of therapy, complete resolution of mucocutaneous lesions was achieved, and only sporadic milia were appreciable where blisters had previously arisen, especially on the buttocks. Therefore, dapsons dosage was halved after 3 months and it was permanently discontinued after 6 months. The patient has not experienced any disease flare-up after nearly 6 years of follow-up.

## Discussion

The precise pathogenetic mechanisms underlying LAD are largely unknown, but its pivotal characteristic seems to be the production and deposition of IgA autoantibodies of the A1 subclass along the dermoepidermal junction.<sup>3,5</sup> Target autoantigens are located within the lamina lucida or, less commonly, the sublamina densa. The former group includes 97-kDa (LABD-97) and 120-kDa (LAD-1) fragments of the extracellular domain of collagen XVII, while collagen VII is usually implicated in the latter.<sup>5</sup> Salt-split skin examination usually reveals IgA deposition on the epidermal side of the vesicle (lamina lucida type), but a dermal pattern (sublamina densa type) is also possible, as well as reactivity on both sides ('mirror image' type).<sup>3</sup> Circulating IgA autoantibodies are detectable in about 70% of patients, especially in children,<sup>5</sup> but mostly with low titers.<sup>3</sup> Histologically, subepidermal vesicles are surrounded by a neutrophil-dominant inflammatory infiltrate; eosinophils are often present and particularly predominant in adult-onset drug-induced LAD.<sup>3,5</sup> Therefore, histologic differential diagnosis with DH and BP can be arduous.

LAD can arise in association with UC. A recent literature review on the topic identified 39 cases of UC-associated LAD. Most patients were male adults (mean age: 39.9 years, range: 8-68), and UC diagnosis preceded the onset of LAD in 94% of cases, with a mean UC duration of 6.1 years. Most frequent treatments for UC included prednisolone, mesalazine, and colectomy and/or proctectomy.<sup>6</sup> It has been suggested that in patients suffering from UC, active or latent inflammation might cause intestinal epithelial damage and exposure of hidden epitopes, which might cross-react with BMZ antigens and trigger autoantibody production.<sup>6</sup>

In iatrogenic LAD, the most frequently involved medication is vancomycin, followed by phenytoin and trimethoprim/sulfamethoxazole. Other antibiotics, non-steroidal anti-inflammatory drugs, antiepileptic and antihypertensive agents can be implicated as well.<sup>3</sup> Culprit medications might stimulate an autoimmune response by either cross-reacting with self-antigens, structurally altering their conformation, or unmasking previously hidden epitopes.<sup>2</sup> In comparison with idiopathic cases, iatrogenic LAD seems to be more frequent in males, and patients are reported to be older (mean age: 66.5 vs. 51 years).<sup>2,3,7</sup> This, however, might be due to the higher number of medications taken by older patients in comparison with younger ones,<sup>2</sup> and other studies did not underline any age difference between idiopathic and iatrogenic LAD.<sup>8</sup> While some reports highlight how drug-induced LAD rarely affects mucous membranes, no significant discrepancy in terms of mucosal involvement emerged between idiopathic and iatrogenic forms in more recent works.<sup>8</sup> In fact, no specific clinical difference can be identified, even though iatrogenic LAD tends to be more severe, extensive, and atypical.<sup>2</sup> Fortuna *et al.* underlined how drug-induced LAD should be suspected when cutaneous lesions rapidly resolve after medication suspension, as happened in our case, sometimes even without the need for systemic treatment; when further investigation is possible, linear IgA deposits along the dermoepidermal junction and circulating autoantibodies against the BMZ are no longer present after drug withdrawal.<sup>3</sup> Latency before the onset of cutaneous manifestations is highly variable (1-780 days),<sup>3</sup> but usually less than one month.<sup>2,3</sup>

The occurrence of LAD after metronidazole administration has been reported twice before, always in combination with ceftriaxone (table 1).<sup>9,10</sup> A 80-year-old female suffering from cholelithiasis with concomitant cholecystitis developed a histologically confirmed cutaneous LAD 13 days after metronidazole and ceftriaxone initiation; after medication withdrawal, she was administered oral prednisone, and clinical remission was achieved within 6 weeks. No cutaneous exacerbation occurred after 1 year of follow-up. Interestingly, a diagnosis of drug-induced LAD was made based on both temporal plausibility and detection of ceftriaxone- and metronidazole-specific T cells in the patient's peripheral blood.<sup>9</sup> The other patient was a 64-year-old female who was administered intravenous ceftriaxone and metronidazole for a liver abscess and later developed a generalized

oedema. After 18 days, a morbilliform rash appeared on the patient's trunk and subsequently evolved into bullous lesions. Kidney and skin biopsies were performed, and a diagnosis of IgA nephropathy in association with LAD was made. Skin lesions cleared about 14 days after antibiotic discontinuation and systemic corticosteroid treatment, while renal function recovered more slowly.<sup>10</sup> In our case, we suspected a metronidazole-induced form of LAD mostly based on the 2-week time latency between antibiotic intake and dermatosis onset, alongside the rapid and excellent clinical response obtained after medication withdrawal and only one month of systemic treatment. We calculated a Naranjo score of 5 (probable adverse drug reaction). It is possible that in our patient, underlying UC acted as a predisposing or concurrent precipitating factor in inducing LAD.

## Conclusions

LAD is a rare and often challenging entity in terms of successful treatment. To our knowledge, this is the third report of metronidazole-induced LAD, and the first in which metronidazole was not administered in association with ceftriaxone. Hence, we believe that metronidazole should be considered as possibly responsible when a case of iatrogenic LAD is suspected, although it seems to be infrequently implicated. Our case also underlines how discontinuation of the offending drug is crucial, as it leads to a quicker clinical remission and reduces the need for systemic treatment. Furthermore, when the culprit medication is no longer administered, prognosis is excellent and disease flare-ups unusual.

## References

1. Shin L, Gardner JT 2nd, Dao H Jr. Updates in the diagnosis and management of linear IgA disease: A systematic review. *Medicina (Kaunas)*. 2021 Aug 12;57(8):818.
2. Lammer J, Hein R, Roenneberg S, Biedermann T, Volz T. Drug-induced linear IgA bullous dermatosis: A case report and review of the literature. *Acta Derm Venereol*. 2019 May 1;99(6):508-515.
3. Fortuna G, Marinkovich MP. Linear immunoglobulin A bullous dermatosis. *Clin Dermatol*. 2012 Jan-Feb;30(1):38-50.
4. Mori F, Saretta F, Liotti L, Giovannini M, Castagnoli R, Arasi S, Barni S, Mastroianni C, Pecoraro L, Caminiti L, Marseglia GL, Barbaud A, Novembre E. Linear immunoglobulin A bullous dermatosis in children. *Front Pediatr*. 2022 Jul 8;10:937528.
5. Tekin B, Johnson EF, Wieland CN, Gibson LE, Camilleri MJ, Kalajji AN, Comfere NI, Peters MS, Lehman JS. Histopathology of autoimmune bullous dermatoses: what's new? *Hum Pathol*. 2022 Oct;128:69-89.
6. Kanda N, Nakadaira N, Otsuka Y, Ishii N, Hoashi T, Saeki H. Linear IgA bullous dermatosis associated with ulcerative colitis: A case report and literature review. *Australas J Dermatol*. 2020 Feb;61(1):e82-e86.
7. Waldman MA, Black DR, Callen JP. Vancomycin-induced linear IgA bullous disease presenting as toxic epidermal necrolysis. *Clin Exp Dermatol*. 2004 Nov;29(6):633-6.
8. Chanal J, Ingen-Housz-Oro S, Ortonne N, Duong TA, Thomas M, Valeyrie-Allanore L, Lebrun-Vignes B, André C, Roujeau JC, Chosidow O, Wolkenstein P. Linear IgA bullous dermatosis: comparison between the drug-induced and spontaneous forms. *Br J Dermatol*. 2013 Nov;169(5):1041-8.
9. Yawalkar N, Reimers A, Hari Y, Hunziker T, Gerber H, Müller U, Pichler W. Drug-induced linear IgA bullous dermatosis associated with ceftriaxone- and metronidazole-specific T cells. *Dermatology*. 1999;199(1):25-30.
10. Kim JS, Choi M, Nam CH, Kim JY, Park BC, Kim MH, Hong SP. Concurrent drug-induced linear immunoglobulin A dermatosis and immunoglobulin A nephropathy. *Ann Dermatol*. 2015 Jun;27(3):315-8.

**Figure 1: a) vesicular lesions with symmetrical distribution and extensive involvement of the back, buttocks and lower limbs; b) enlargement of vesicular lesions with annular arrangement and “string of pearls” appearance; c) lesions in the oral mucosa with involvement of the hard palate; d) genital involvement; e) haematoxylin-eosin histological image of a vesicle, which has serum haematic content and eosinophilic infiltrate; f) salt split skin: positive for IgA on the epidermal side.**

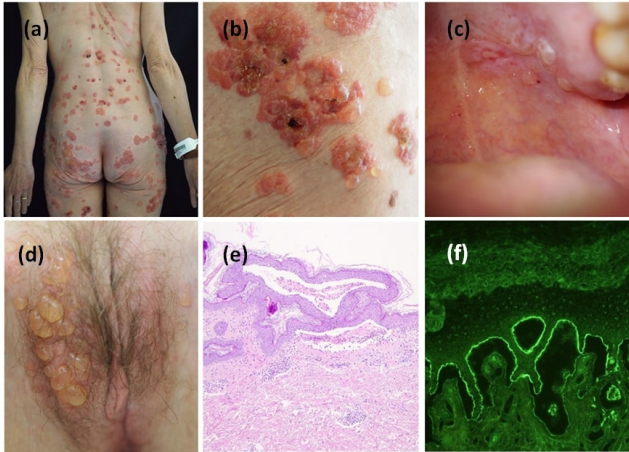


Table 1: description of similar cases of LAD occurring after the use of metronidazole											
Author s	Y ear	Patie nt age at diagnosis	Patie nt sex	Concomit ant diseases	Culprit medication	Clinical manifestation	Histolog ical examina tion	DIF	IIF	Treatment	Follow-up
Current case	2023	51	F	Ulcerative colitis	Metronidazole 500 mg every 8 hours	Multiple round erythematous-edematous plaques and tense vesiculobullous lesions involving axillae, trunk, genitals, buttocks, with a symmetric distribution.. The oral mucosa was also involved	subepidermal blister with infiltrate of neutrophils and eosinophils	Linear IgA deposition along the dermoepidermal junction	Negative	Discontinuation of the drug. Oral methylprednisolone 16 mg/die with subsequent tapering over 20 days and oral dapsone 50 mg/die	Complete resolution of mucocutaneous lesions after 1 months of therapy. disease flare-up after nearly 6 years of follow-up
Kim JS, Choi M, Nam CH, et al. <sup>10</sup>	2015	64	F	Liver abscess	Metronidazole + Ceftriaxone	Pruritic diffuse morbilliform rash, purpuric macules and papules, bullae on axilla and neck, blood eosinophilia, immunoglobulin A nephropathy. Mucous membranes were not involved.	Subepidermal blister	Linear IgA deposition along the dermoepidermal junction. Diffuse mesangial IgA deposits also at the kidney biopsy	Not done	Discontinuation of the drugs. Intravenous dexamethasone, steroid ointment immediately after bullae formation. Oral prednisone 60 mg/die one week after bullae formation, replacing intravenous steroid treatment	Skin lesions subsided within two weeks. Routine follow-up for kidney function which recovered slowly
Yawalkar N, Reimers A, Hari Y, et al. <sup>9</sup>	1999	80	F	Cholelithiasis with concomitant cholecystitis	Metronidazole + Ceftriaxone	Numerous erythematous, partly urticarial plaques on the trunk. Multiple, tense, partly hemorrhagic blisters on the trunk and distal extremities developed 4 days later. Peripheral leucocytosis with eosinophilia. Mucous membranes were not	Subepidermal blister. Polymorphonuclear infiltrate and perivascular lymphocytes.	Strong deposition of IgA (linear) and C3 (granular) along the epidermal basement membrane zone	Negative	Discontinuation of the drugs. 50 mg/die prednisone for 8 days	Erosions healed within 6 weeks. On a follow-up examination 1 year later the patient had no signs of recurrence.

						involved					
--	--	--	--	--	--	----------	--	--	--	--	--