

Carugno Andrea (Orcid ID: 0000-0002-8231-2205)
Parietti Michele (Orcid ID: 0000-0003-4673-4635)
Cicarese Giulia (Orcid ID: 0000-0001-8363-0195)
Campanati Anna (Orcid ID: 0000-0002-3740-0839)
Diotallevi Federico (Orcid ID: 0000-0003-2274-1742)
ATZORI Laura (Orcid ID: 0000-0002-8105-1402)
Caccavale Stefano (Orcid ID: 0000-0001-7433-9283)
Bellinato Francesco (Orcid ID: 0000-0002-6163-6921)

Title: “Clinical-epidemiological aspects of the Monkeypox 2022 epidemic: a multicenter study by the Italian SIDeMaST Group of Sexually Transmitted, Infectious and Tropical Diseases”

Key words: monkeypox (mpox), infectious disease, viral infection, global health, vaccine, sexually transmitted diseases

Word count: 600; Table count: 1; Figure count: 1

Authors: A. Carugno*^{1,2}, M. Parietti*¹, G. Ciccarese³, A. Campanati⁴, F. Diotallevi⁴, L. Atzori⁵, R. Balestri⁶, S. Caccavale⁷, F. Bellinato⁸, S.V. Benatti⁹, S. Venturelli⁹, P. Vezzoli¹, P. Sena¹, M. Papini¹⁰
*Authors share first authorship

Affiliations:

¹Dermatology Unit, ASST Papa Giovanni XXIII, Bergamo, Italia.

²Ph.D. Program in Molecular and Translational Medicine (DIMET), University of Milan-Bicocca, Milan, Italy

³Unit of Dermatology, Department of Medical and Surgical Sciences, University of Foggia, Foggia, Italy.

⁴Department of Clinical and Molecular Sciences-Dermatological Clinic, Polytechnic Marche University, Ancona, Italy

⁵Dermatology Clinic, Department of Medical Sciences and Public Health, University of Cagliari, Cagliari, Italy.

⁶Division of Dermatology, Trento Hospital, Trento, Italy

⁷Dermatology Unit, Department of Mental and Physical Health and Preventive Medicine, University of Campania Luigi Vanvitelli, Naples, Italy

⁸Department of Medicine, Section of Dermatology and Venereology, University of Verona, Verona, Italy

⁹Infectious Diseases Unit, ASST Papa Giovanni XXIII, Bergamo, Italia.

¹⁰Department of Medicine and Surgery, University of Perugia, Dermatology Clinic of Terni.

Conflicts of Interest and Source of Funding: none declared.

Corresponding author:

Michele Parietti, MD

Dermatology Unit

ASST Papa Giovanni XXIII Hospital,

Piazza OMS 1, Bergamo, Italy

Phone number: +39 035 2676183

pariettimichele@gmail.com

Ethics Statement: The patients in this manuscript have given written informed consent to the publication of their case details.

This article has been accepted for publication and undergone full peer review but has not been through the copyediting, typesetting, pagination and proofreading process which may lead to differences between this version and the [Version of Record](#). Please cite this article as doi: [10.1111/jdv.19265](https://doi.org/10.1111/jdv.19265)

The data that support the findings of this study are available from the corresponding author upon reasonable request.

Dear Editor,

In spring 2022, an increase of monkeypox (mpox) cases was reported in Europe. Mpox is a zoonotic virus of the Poxviridae family, is endemic in the Congo Basin and just few cases outside Africa were reported before 2022. Its cutaneous presentation is similar to smallpox, usually preceded by a prodromal phase of fever, lymphadenopathy, headache and asthenia.¹ Infection can occur through various means, including skin-to-skin contact, respiratory droplets or contact with fomites.² The new outbreak is unique due to the increased human-to-human transmission, without an animal reservoir, particularly among men who have sex with men (MSM).^{3,4} As of February 13, 2023, 85.860 confirmed cases have been reported in 110 countries.⁵

We collected 34 cases of mpox infection (Table 1, Figure 1), all male, median age of 35 (IQR:19-59). Of these cases, 97% yielded positive results in vesicular swabs while 78% tested positive for mpox DNA in throat swabs using PCR. 88% of the patients were MSM, with 15% being people living with HIV (PLWH) on antiretroviral therapy and 24% taking pre-exposure prophylaxis (PrEP) for human immunodeficiency virus (HIV). 42% had a history of sexually transmitted disease (STD). All patients had skin manifestations, with 33% reporting skin lesions before developing systemic signs/symptoms (mean: 7 days before, IQR:1-10). The majority of patients exhibited systemic signs/symptoms, with fever being the most common (70%). Lymphadenopathy was less frequent than in previous studies. 85% of patients presented with multiple skin lesions, such as papules, pustules, vesicles, ulcers, or a combination thereof. Pustules and vesicles often progressed to ulcers, and a minority of cases exhibited urticarial lesions, diffuse papular erythema, and vegetative crusted lesions. Lesions were predominantly found in specific regions, with genital lesions in 46%, anal lesions in 36%, and facial lesions in 39% of cases. The presence of ano-genital and oral lesions suggests a possible sexual transmission of mpox. Diffuse lesions affecting the trunk and limbs were observed in 45% of cases. The mean duration of skin lesions was 13 days (IQR:5-40). No significant difference in disease expression was observed between the four mpox-positive swab patients who had received anti-variola vaccination and unvaccinated subjects. Co-infection with other STDs was observed in 35% of patients, with gonorrhoea being the most commonly reported. Skin co-infections were found in 9% of cases, and severe inflammatory proctitis led to hospitalization in one patient. All patients recovered within 21 days, except for one patient who

experienced recurrent lesions and required a second isolation period. Treatment was administered to few patients and involved topical medications such as antiseptics, topical antibiotics, and analgesics.

Our patient cohort data supports findings published by the European Centre for Disease Prevention and Control (ECDC) indicating that the 2022 outbreak primarily affected men aged 18-50, particularly MSM.^{3,4} The spread of mpox among MSM groups with multiple partners was likely facilitated by sexual practices.^{3,4} The general population has a low risk of infection, while people with multiple sexual partners face a moderate risk.⁶ This outbreak differed from previous outbreaks in endemic countries as cutaneous signs were often the first indication of infection, with skin lesions appearing on the anogenital and perioral regions.^{7,8} Scarring was a potential long-term sequela observed in 30% of cases.⁹ Prodromal signs/symptoms were mild, and subclinical cases were reported. Recent sequencing data showed that the mpox strains detected in Europe correspond to the West African clade, which is considered less virulent and less contagious.⁷ Screening for STDs is crucial as co-infections are common.¹⁰ The outbreak has substantially declined since September 2022, with only 108 cases identified in the first four weeks of 2023.⁵ However, sustained vigilance is necessary in case of a resurgence of cases.

Figure legend

Figure 1. (a) Eschar-like lesions on the chin. (b) Umbilicated papules on the back of the hands. (c) Umbilicated papule on the trunk. (d) Perioral pustules and abscess on the right cheek. (e) Papules with central umbilication and progressive central necrosis on the penile shaft. (f) Papule-pustule evolved into a crusted lesion after topical treatment for suspected molluscum contagiosum.

References

1. Bunge EM, Hoet B, Chen L, et al. The changing epidemiology of human monkeypox-A potential threat? A systematic review. *PLoS Negl Trop Dis*. 2022 ;**16**:e0010141.
2. Centers for Disease Control and Prevention (CDC). Human monkeypox -- Kasai Oriental, Democratic Republic of Congo, February 1996-October 1997. *MMWR Morb Mortal Wkly Rep*.1997;**46**:1168-71.
3. Kupferschmidt K. Why monkeypox is mostly hitting men who have sex with men. *Science*. 2022;**376**:1364-1365.

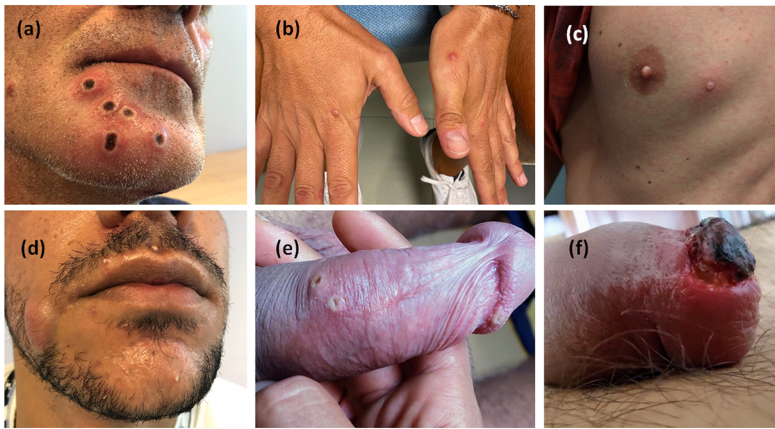
- Accepted Article
4. Vusirikala A, Charles H, Balasegaram S, et al. Epidemiology of Early Monkeypox Virus Transmission in Sexual Networks of Gay and Bisexual Men, England, 2022. *Emerg Infect Dis.* 2022;**28**:2082-2086.
 5. European Centre for Disease Prevention and Control (ECDC) 2022 Mpox situation update. Available at: <https://www.ecdc.europa.eu/en/news-events/monkeypox-situation-update> (last accessed 14 February 2023).
 6. Zachary KC, Shenoy ES. Monkeypox transmission following exposure in healthcare facilities in nonendemic settings: Low risk but limited literature. *Infect Control Hosp Epidemiol.* 2022;**43**:920-924.
 7. Kumar N, Acharya A, Gendelman HE, Byrareddy SN. The 2022 outbreak and the pathobiology of the monkeypox virus. *J Autoimmun.* 2022;**131**:102855.
 8. Thornhill JP, Barkati S, Walmsley S, et al. Monkeypox Virus Infection in Humans across 16 Countries - April-June 2022. *N Engl J Med.* 2022;**387**:679-691.
 9. Prasad S, Casas CG, Strahan AG, et al. A dermatologic assessment of 101 mpox (monkeypox) cases from 13 countries during the 2022 outbreak: skin lesion morphology, clinical course, and scarring. *J Am Acad Dermatol.* 2023;**88**:1066-1073.
 10. Ciccarese G, Di Biagio A, Bruzzone B, et al. Monkeypox outbreak in Genoa, Italy: clinical, laboratory, histopathologic features, management and outcome of the infected patients. *J Med Virol.* 2023 Feb 9. Epub ahead of print.

	Total (n, %) (N = 34)
Symptoms	
Skin lesions or rash	34 (100%)
Fever	24 (70%)
lymphadenopathy	19 (55%)
Intense asthenia	10 (30%)
muscle pain	6 (18%)
headache	3 (9%)
no systemic symptoms	4 (12%)
Intense localized pain	2 (6%)
Type of skin lesions	
Papules-pustules	24 (70%)
Vesicles	21 (61%)
Ulcers	19 (55%)
Petechiae	1 (3%)
Urticarial pimples	1 (3%)
Diffuse erythema	1 (3%)
Vegetating crusty lesions	1 (3%)
Number of lesions at clinical evaluation	
1	5 (15%)
2-10	18 (52%)
11-20	7 (21%)
>20	3 (9%)
Unknown	1 (3%)
Anatomical Site of cutaneous lesions	
Genitals	16 (46%)
Face	13 (39%)
Anus	12 (36%)
Spread to trunk and limbs	15 (45%)
Co-infection with mpox	
Gonorrhea	5 (15%)
Chlamydia	3 (9%)
Syphilis	3 (9%)
Herpes simplex	1 (3%)
Varicella Zoster	1 (3%)
Recent foreign travels	
France	2 (6%)
United Kingdom	2 (6%)
Spain (Canary Islands)	2 (6%)
Germany	1 (3%)
United States	1 (3%)
Taiwan	1 (3%)
None	25 (73%)

Table 1. Characteristics of the population. This study was conducted in collaboration with the STD group of the Italian Society of Medical, Surgical, Aesthetic Dermatology and Sexually Transmitted Diseases (SIDeMaST). The cases of mpox were diagnosed both clinically and through

laboratory confirmation by dermatologists or infectiologists across seven centers in Italy. A questionnaire was used to collect demographic and clinical data for all diagnosed cases. The observation period was from May 25th to November 22nd, 2022, and registration for the study was open to SIDeMaST registered dermatologists. The cases were reported from Bergamo (56%), Genoa (26%), Ancona (6%), Trento (3%), Naples (3%), Cagliari (3%), and Verona (3%).

Accepted Article



jeadv-2023-0555-File003.tif