

# Restoration of the Vertical Posterior Dimension in a Grinding Patient before Orthodontic Treatment: A Case-Report with Electromyographic Evaluation of Masticatory Muscles Balance

Bianco Edoardo\*, Attuati Sara, Brugali Cristina, Nanussi Alessandro and Maddalone Marcello

*University of Milano Bicocca, Department of Medicine and Surgery, Monza, Italy*

**Abstract:** *Aim:* the aim of this article is to assess the importance of masticatory muscles balance evaluation before improving vertical dimension through conservative and restorative techniques. It also shows how a multidisciplinary approach is needed to obtain a better result for the patient.

*Background:* Bruxism is defined as the parafunctional activity of grinding or clenching of teeth. Management of severe worn dentition in patients with bruxism is challenging since this condition can lead to loss of tooth structure and occlusal vertical dimension (OVD). In some cases the impossibility to correct the proclination of the maxillary incisors occurs due to the posterior tooth wear.

*Case Description:* an orthodontic alignment was obtained after having improved posterior vertical dimension according to an electromyographical analysis using Teethan® electromyographic system. The activity of anterior temporals and masseters was controlled and balanced by electromyography at every step of the treatment.

*Conclusion:* an unbalanced dental occlusal function can compromise the stability of an orthodontic treatment; it is important an evaluation from different points of view in order to rehabilitate the patient in his complex.

*Clinical significance:* electromyography proved itself to be a useful tool in the hands of the clinician to check the oral muscles balance and to avoid temporomandibular joint (TMJ) overload in restorative dentistry, prosthodontics and orthodontics.

**Keywords:** Electromyography, Gnathology, Hawley retainers, Onlay, Oral, Orthodontic, Posture, Reduced vertical dimension, Teethan, TMJ and occlusion.

## INTRODUCTION

Management of severe worn dentition in patients with bruxism is challenging since this condition can lead to loss of tooth structure and occlusal vertical dimension, temporomandibular implications, tooth hypersensitivity and masticatory or aesthetic impairment. This condition can be associated to bruxism. According to the American Academy of Sleep Medicine, bruxism can be defined as the repetitive muscle activity of the jaw characterized by clenching or grinding of teeth and/or bracing or thrusting of the mandible [1].

Bruxism is defined as the parafunctional activity of grinding or clenching of teeth. There are several signs and symptoms related to bruxism besides tooth wear: hypertrophied masticatory muscles, periodontal disease, abfraction in the cervical region of the teeth, occlusal pits and temporomandibular joint pain [2, 3].

The damage of tooth wear is permanent and will thus compromise the dentition for the total lifetime. This may require repeated and increasingly complex restorations. Literature reported that the best solution is mainly focused on the restorative management strategies [4, 5].

Electromyography is a non-invasive exam which evaluates the masticatory muscles activity by facial application of electrodes on masseter and temporal muscles. In the last ten years, several studies demonstrated the effectiveness and reproducibility of surface electromyography in the objective evaluation of temporal muscle and masseter activity, thus evaluating the effect of occlusion on the aforementioned muscle balance [6-9].

## METHODS

A healthy 26-year-old man sought orthodontic consultation to correct the proclination of anterior mandibular teeth and the increased overjet.

Intraoral evaluation shows 1 mm diastema between the central incisors, the upper dental midline was centered. The molar relationship of the patient's right

\*Address correspondence to this author at the University of Milano Bicocca, Department of Medicine and Surgery, Monza, Italy;  
Tel: +393487268209;  
E-mail: edoardo.bianco13@gmail.com

side was Class II, while that of the left side was Class I with a tendency to the Class II.

Clinical examination revealed loss of occlusal vertical dimension (OVD) and wearing of occlusal molars surfaces due to overnight clenching and grinding. The patient had never used an oral splint to protect his teeth.

After orthodontic check-up with photographs and study models, it was decided to increase posterior vertical dimension before the orthodontic treatment due to the lack of space for a correct proclination.

A silicone guide was obtained from the wax model of the new dental anatomy of the posterior teeth. The buildup guide was used to provide a resin mock-up (Enamel Plus Temp<sup>®</sup> – Micerium) from the first premolar to the second molar.

A resin luting cement was used for cementing the mock-up in the lower arch on both sides in order to test the increased new vertical dimension.

Surface electromyographs (EMGs) were simultaneously recorded from the left and right superficial masseter and anterior temporalis muscles using the Teethan<sup>®</sup> electromyograph, following the protocol indicated by the manufacturer: the first Teethan<sup>®</sup> record provides electrical information of the muscular system by cotton rolls interposition between the dental arch; the second one is carried out in MVC (maximum voluntary clenching) on teeth. This analysis allowed us to evaluate the occlusal balance and new vertical dimension, checking the Global Neuromuscular Equilibrium Index (a diagram that summarizes the values of the indexes analyzed: percentage of overlapping coefficient (POC), center of balance (BAR), torsion (TORS), maximum strength expressed during clenching (IMP).

The temporary mock-up was maintained for 4 weeks to assess patient's tolerance to the change of OVD and to check any possible interference in patient's ability to speak properly; after that, composite onlays were made based on data obtained by the electromyographical analysis. A few months later another electromyographic evaluation allowed us to control the occlusal balance before the orthodontic treatment and the stability of the new vertical dimension.

The occlusal plane elevation allowed us to get space to correct anterior teeth proclination, Hawley retainer with an elastic chain was used to improve

dental alignment. At the end of the orthodontic treatment, the occlusion was stabilized with a Michigan oral splint to protect teeth surfaces from bruxism and grinding and to reduce load on temporomandibular joint.

## DISCUSSION

The rehabilitation of worn dentition usually includes extensive treatment approaches. The case presented showed signs of tooth wear which were attributed to bruxism. Trying to maximize aesthetics without compromising the strength and durability of the restorations and using a conservative clinical protocol, a treatment option using composites onlays together with orthodontic treatment was chosen.

The restorative approaches for patients with bruxism and worn dentition may be performed with direct or indirect restorations such as direct resin composites or metal, gold, and ceramic and laboratory composites to make onlays or crowns, alone or in combination. In cases of severely worn dentition tooth preparation for complete crowns in an alternative to onlays to obtain an increase on the occlusal vertical dimension [10].

The surface electromyography allows to calculate the electric field potential resulting from the overlap of the action potentials of every single active muscle fiber. In clinical practice the evaluation of the recorded signal, defined "rough", permits to identify only any decrease or increase of muscle contraction in a specific period, or the muscle turn off. The advantage from the modern electrical devices is to process the rough signal and put the muscle contraction into a graphic.

The signal detection is recognised by a bipolar electrode put on the skin surface, upon the belly of the muscle. The potential variation of the single motor units represents the electric activity of the muscle, which passes from release to contraction. Compared to the needle electromyography, this surface technique gives a more global information about muscle activity, because the action potentials detected are the summation of different motor units potentials that reach the skin-electrode surface. The surface technique has been preferred for a lower invasiveness, the capacity of evaluate the complete muscle activity and the absence of muscle tension caused by electrode-needle attaching. In order to evaluate the occlusion role and influence on muscle activity, MVC record is compared to an EMG record in centric relation, without considering occlusion interference. This process, named normalization, is conventionally achieved

putting cotton rolls distal to canines so that occlusion may be excluded and muscle activity is the only information revealed. The reference point is represented by an imposed stability condition; any other state to analyse is automatically related to this reference condition which give the percentage between every single canal and the reference one, expressed in microvolt. This method allows to delete every external perturbations in the electric signal. In the present case report the Authors it is important to get a good global index of neuromuscular adaption without any lateral torsion or anterior or posterior occlusal overload [6-9, 11].

To decrease the deleterious effects of bruxism the use of interocclusal appliances such as hard occlusal stabilization splints or soft mouthguards has been proposed in literature. Although there are some controversial results on the efficacy of occlusal splints in the management of bruxism, they have a fundamental role on the prevention and limitation of teeth damage caused by this disorder [12].

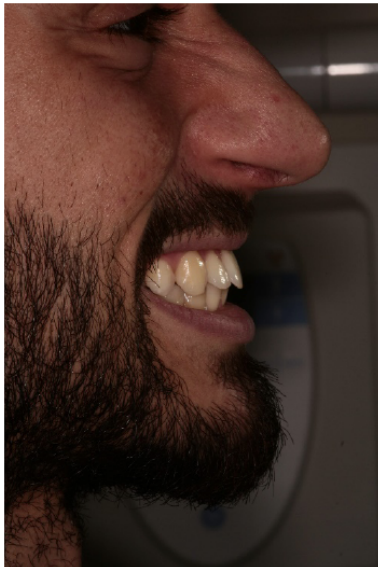

Figure 1: initial situation (lateral).

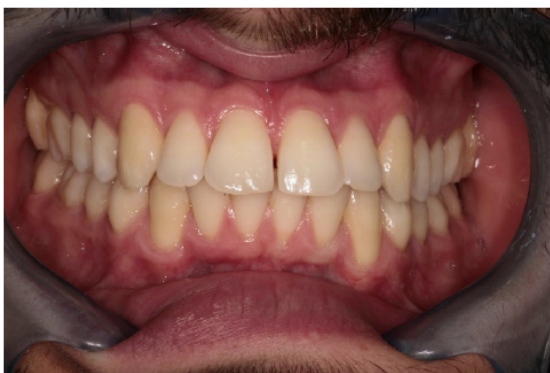

Figure 2: initial situation (frontal view).

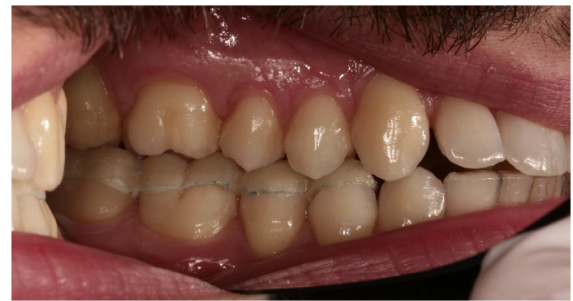

Figure 3: provisional onlays (left side).

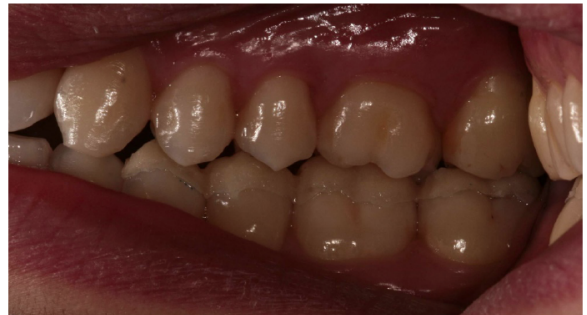

Figure 4: provisional onlays (right side).

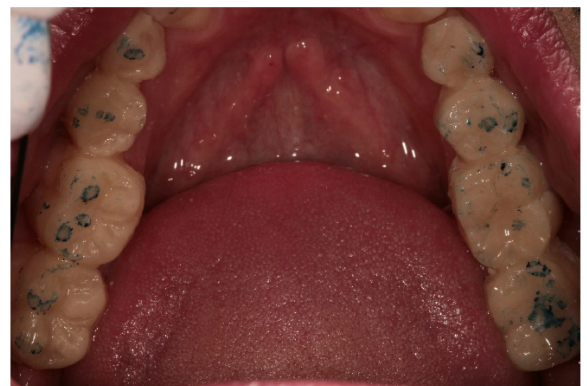

Figure 5: occlusion with the temporary resin onlays.

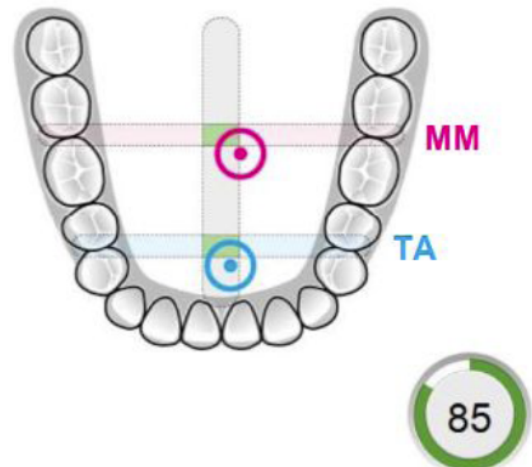
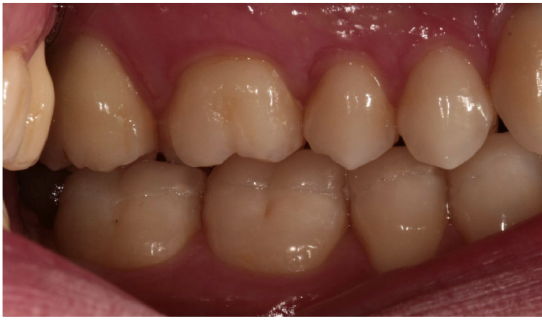
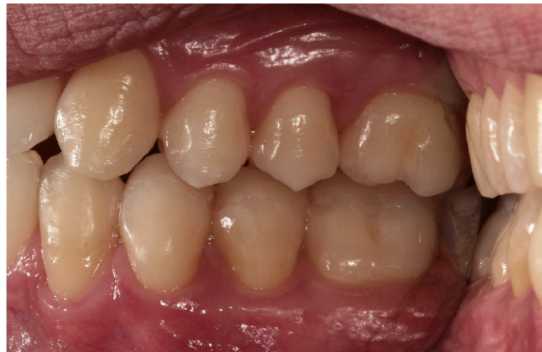
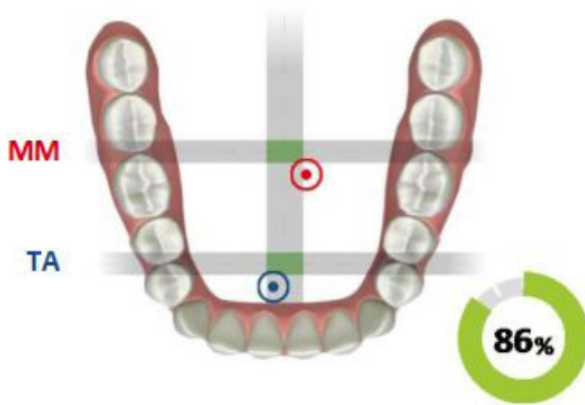Figure 6: electromyographic analysis with provisional onlays.



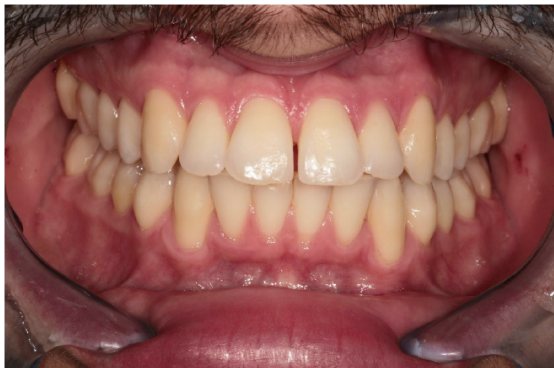**Figure 7:** composite onlays made based on data obtained by the electromyographical analysis (left side)



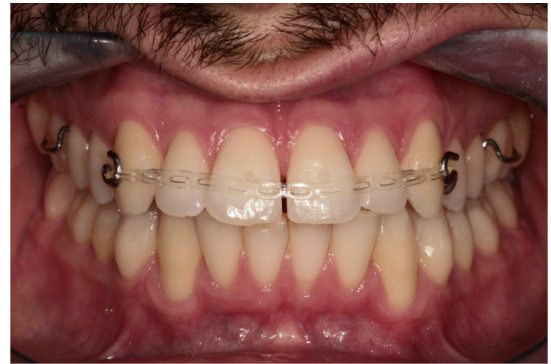**Figure 8:** composite onlays made based on data obtained by the electromyographical analysis (right side).



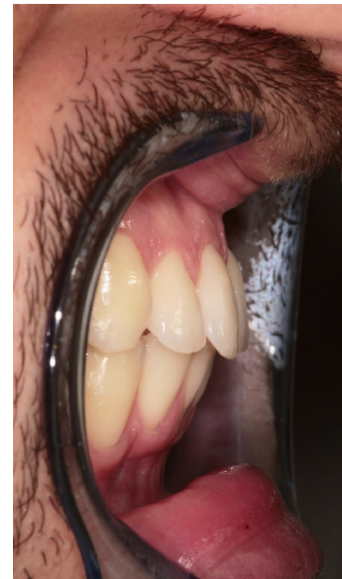**Figure 9:** electromyographic analysis with definitive onlays.



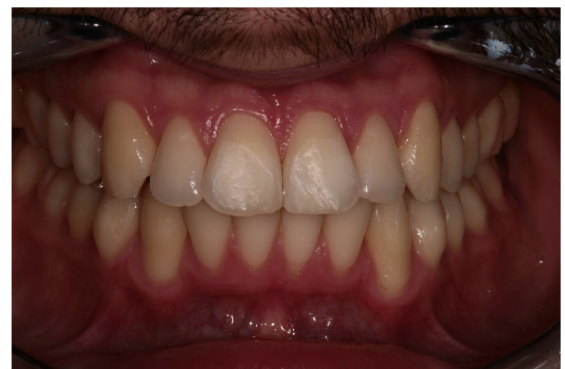**Figure 10:** New occlusion with composite onlays (frontal view).



**Figure 11:** Hawley retainer with an elastic chain was to improve dental alignment.



**Figure 12:** end of the treatment: lateral.



**Figure 13:** end of the treatment (frontal).

**CONCLUSIONS**

The positioning of posterior occlusal onlays has proved to be a valid instrument to rehabilitate the lost vertical dimension while restoring the dento-facial harmony. The electromyographical evaluation was useful to control the patient's response to the treatment

to avoid occlusal overload which can lead to muscle pain and discomfort due to the bad tolerance of the altered vertical dimension. After 1 year from the end of the treatment no signs or symptoms of discomfort were recorded, and the aesthetic result is stable.

## REFERENCES

- [1] Wetselaar P, Lobbezoo F. The tooth wear evaluation system: a modular clinical guideline for the diagnosis and management planning of worn dentitions. *J Oral Rehabil* 2016; 43(1): 69-80. <https://doi.org/10.1111/joor.12340>
- [2] Deng H, Gao S, Lu S, Kumar A, Zhang Z, Svensson P. Alteration of occlusal vertical dimension induces signs of neuroplastic changes in corticomotor control of masseter muscles: Preliminary findings. *J Oral Rehabil* 2018; 45(9): 710-719. <https://doi.org/10.1111/joor.12682>
- [3] Terebesi S, Giannakopoulos NN, Brüstle F, Hellmann D, Türp JC, Schindler HJ. Small vertical changes in jaw relation affect motor unit recruitment in the masseter. *J Oral Rehabil* 2016; 43(4): 259-68. <https://doi.org/10.1111/joor.12375>
- [4] Shellis RPM. The interactions between attrition, abrasion and erosion in tooth wear *Monogr Oral Sci* 2014; 25: 32-45. <https://doi.org/10.1159/000359936>
- [5] Tsiggos N, Tortopidis D, Hatzikyriakos A, Menexes G. Association between self-reported bruxism activity and occurrence of dental attrition, abfraction, and occlusal pits on natural teeth. *J Prosthet Dent* 2008; 100(1): 41-6. [https://doi.org/10.1016/S0022-3913\(08\)60135-3](https://doi.org/10.1016/S0022-3913(08)60135-3)
- [6] Tartaglia GM, Lodetti G, Paiva G, De Felicio CM, Sforza C. Surface electromyographic assesment of patients with long lasting temporomandibular joint disorder pain. *J Electromyogr Kinesiol* 2011. <https://doi.org/10.1016/j.jelekin.2011.03.003>
- [7] Kacprzak A, Strzecki A. Methods of accelerating orthodontic tooth movement: A review of contemporary literature. *Dent Med Probl* 2018 ; 55(2): 197-206. <https://doi.org/10.17219/dmp/90989>
- [8] Tartaglia GM. Electromyographic analysis of masticatory and neck muscles in subjects with natural dentition, teeth-supported and implant-supported prostheses. *Clin Oral Implants Res* 2008. <https://doi.org/10.1111/j.1600-0501.2008.01574.x>
- [9] De Felicio CM, Tartaglia GM. Electromyographic standardized indices in healthy Brazilian young adults and data reproducibility. *J Oral Reahabil* 2009. <https://doi.org/10.1111/j.1365-2842.2009.01970.x>
- [10] Manicone PF, Rossi Iommetti P, Raffaelli L. An overview of zirconia ceramics: basic properties and clinical applications. *Journal of Dentistry* 2007; 35(11): 819-826. <https://doi.org/10.1016/j.jdent.2007.07.008>
- [11] Castroflorio T, Bracco P, Farina D. Surface electromyography in the assesment of jaw elevator muscles. *J oral Rehabil*.2008. <https://doi.org/10.1111/j.1365-2842.2008.01864.x>
- [12] Okeson J. The effects of hard and soft occlusal splints on nocturnal bruxism. *The Journal of the American Dental Association* 1987; 114(6): 788-791 <https://doi.org/10.14219/jada.archive.1987.0165>