

Pediatr Neurosurg , DOI: 10.1159/000526645

Received: June 21, 2022

Accepted: July 30, 2022

Published online: August 19, 2022

Occipital Intradiploic Pseudomeningocele: a rare complication of pediatric posterior cranial fossa surgery. Case Report and Review of the Literature

Bonomo G, Rubiu E, Iess G, Bonomo R, Amato A, Restelli F, Falco J, Mazzapicchi E, Locatelli M, Rampini P, Carrabba GG

ISSN: 1016-2291 (Print), eISSN: 1423-0305 (Online)

<https://www.karger.com/PNE>

Pediatric Neurosurgery

Disclaimer:

Accepted, unedited article not yet assigned to an issue. The statements, opinions and data contained in this publication are solely those of the individual authors and contributors and not of the publisher and the editor(s). The publisher and the editor(s) disclaim responsibility for any injury to persons or property resulting from any ideas, methods, instructions or products referred to the content.

Copyright:

© 2022 S. Karger AG, Basel

Occipital Intradiploic Pseudomeningocele: a rare complication of pediatric posterior cranial fossa surgery. Case Report and Review of the Literature

Giulio Bonomo, * • MD, ^{a, b} Emanuele Rubiu, • MS, ^{a, b} Guglielmo Iess, MD, ^{a, b} Roberta Bonomo, MD, ^c Alessia Amato, MD, ^d Francesco Restelli, MD, ^b Jacopo Falco, MD, ^b, Elio Mazzapicchi, MD, ^b Marco Locatelli, MD, PhD, ^{a, e, f} Paolo Rampini, MD, ^a and Giorgio G. Carrabba, MD, PhD ^a

• These authors contributed equally to this work

^a Department of Neurosurgery, Fondazione IRCCS Ca' Granda Ospedale Maggiore Policlinico, Milan, Italy; ^b University of Milan, Milan, Italy; ^c Experimental Neurology Unit, School of Medicine and Surgery, University of Milano-Bicocca, Monza, Italy; ^d Department of Child Neuropsychiatry, ASST Santi Paolo e Carlo, Milan, Italy; ^e Dino Ferrari Center, Neuroscience Section, Department of Pathophysiology and Transplantation, University of Milan, Milan, Italy; ^f Aldo Ravelli Center for neurotechnology and experimental brain therapeutics, Milan, Italy

* Corresponding author:

Giulio Bonomo, MD

Department of Neurosurgery, Fondazione IRCCS Ca' Granda Ospedale Maggiore Policlinico

Via Francesco Sforza, 20122, Milan, Italy

Tel.: +39 02 55035502; +39 320 0817726

E-mail: dott.giuliobonomo@gmail.com

ORCID: <https://orcid.org/0000-0002-4749-7929>

Keywords: Intradiploic, intraosseus, pseudomeningocele, occipital, pseudocyst, late-onset, CSF leak, CSF fistula

Word count paper: 1383; **Word count abstract:** 194.

Number of Tables: 1

Number of Figures: 2

Running title: Occipital Intradiploic Pseudomeningocele

Abbreviations: CISS: Constructive Interference in Steady State; CSF: cerebrospinal fluid; CT: computed tomography; DWI: Diffusion-Weighted Imaging; OIP: occipital intradiploic pseudomeningocele; MRI: magnetic resonance imaging.

Abstract

Introduction: Intradiploic pseudomeningoceles, also called intradiploic cerebrospinal fluid (CSF) fistulas, are abnormal CSF collection between the two bony tables of the calvaria resulting from post-surgical CSF leakage. To date, only six cases of intradiploic pseudomeningocele have been reported, all occurring in the occipital area. In this paper, we report the seventh case of late-onset occipital intradiploic pseudomeningocele (OIP) occurring in a young female patient who underwent surgery for the removal of a cerebellar pilocytic astrocytoma. At this regard, we also review the literature on the few recognized cases of OIP.

Case presentation: The case of an 18-year-old female patient known to our institute for an operation 12 years earlier to remove a pilocytic astrocytoma is illustrated. At admission the patient complained only of occasional orthostatic headache. Brain imaging demonstrated a pseudomeningocele extended intradiploically from the

occipital squama to the condylar and clivus regions, thinning both occipital bone tables and dilating the CSF-filled diploe. Watertight duroplasty and cranioplasty were effectively performed.

Conclusion: Pediatric patients undergoing posterior cranial fossa craniotomy/craniectomy may postoperatively develop OIP. In this setting, treatment of any dural CSF fistula should be considered because of the risk of progressive extension and bone erosion.

Established Facts

- Intradiploic pseudomeningoceles, also called intradiploic cerebrospinal fluid (CSF) fistulas, are abnormal CSF collection between the two bony tables of the calvaria resulting from post-surgical CSF leakage.
- To date, only six cases of intradiploic pseudomeningocele have been reported, all occurring in the occipital area

Novel Insights

- This type of lesion is usually mistaken for intradiploic arachnoid cysts, which are of a different pathogenetic origin.
- We attempt to define the clinical, pathogenetic and radiological characteristics of a new entity, occipital intradiploic pseudomeningocele (OIP), as a complication of pediatric surgery in the posterior cranial fossa.
- Surgical treatment should be adopted even if OIP is accidentally detected in an asymptomatic patient because of its natural tendency towards a slow but progressive enlargement leading to structural weakening of the skull base, including the occipital condyles.
- The goal of surgery is to seal the dural cleft, aspirate the intradiploic CSF collection and seal the diploe in order to prevent liquoral re-infiltration.

Introduction

Intradiploic cerebrospinal fluid (CSF) collections are very rare entities and can be subdivided into two main categories. The first of congenital, traumatic or post-surgical origin, is called intradiploic (or intraosseous) arachnoid (or leptomenigeal) cyst and features its own arachnoid wall (hence the cyst) which, after dural fissuration, herniates into the intradiploic space, usually through a fracture of the inner bony table. The other category includes intradiploic pseudomeningoceles, also called intradiploic CSF fistulas, which are abnormal CSF collection between the two bony tables of the calvaria resulting from post-surgical CSF leakage. This type of lesion is usually mistaken for intradiploic arachnoid cysts, which are of a different pathogenetic origin. [1, 2]

To date, only six cases of intradiploic pseudomeningocele have been reported, all occurring in the occipital area. [1, 3-6]

In this paper, we report the seventh case of late-onset occipital intradiploic pseudomeningocele (OIP) occurring in a young female patient who underwent surgery for the removal of a cerebellar pilocytic astrocytoma. At this regard, we also review the literature on the few recognized cases of OIP, focusing on clinical, and diagnostic data, as well as investigating possible pathogenetic mechanisms to better implement therapeutic strategies.

Case presentation

We present the case of an 18-year-old right-handed female already known to our Institute, where she underwent surgery for the removal of a pilocytic cerebellar astrocytoma at the age of 5 years. One year later, she was reoperated to excise a residual lesion. The patient performed regular annual brain imaging and serial neurosurgical assessments, without evidence of any disease recurrence. Overall, she displayed normal psychophysical development. A brain magnetic resonance imaging (MRI) and computed tomography (CT) at 6-year follow-up revealed a pseudomeningocele. At the 12-year follow-up, the pseudomeningocele extended intradiploically from the occipital squama to the condylar and clival regions, thinning both occipital bone tables and dilating the CSF-filled diploe. (shown in **Fig. 1**) Collaterally, there was a vermian cyst, resulting from the surgical removal of the pilocytic astrocytoma. (shown in **Fig. 1**) At admission she did not present any pathological signs and reported only modest sporadic orthostatic headache. In October 2018, the case was discussed by a multidisciplinary committee which set the indication for revision surgery with eventual dural and cranioplasty surgery. The patient gave written informed consent for the procedure. The day of surgery, the patient was positioned prone. During surgical exploration, a dural and arachnoid cleft communicating with the diploic space through a complete gap between the two thinned bone tables was revealed. The enlarged CSF-filled diploic space resulted in a “blown-glass” appearance of the outer surface of the occipital bone, which was fracturable under instrument pressure (“ping pong” like). (shown in **Fig. 2**) Watertight duroplasty with collagen-based dural graft and cranioplasty with acrylic resin were performed. Postoperative course was uneventful and characterized by early autonomous mobilization. The patient was discharged from our Institute four days after the surgical procedure. She exhibited no signs or symptoms of intracranial hypotension at 4 years follow-up. In addition, radiological follow-up at 4 years demonstrated resolution of the intradiploic pseudomeningocele with stability of the bone thinning and enlargement pattern.

Materials and Methods

Articles reporting intradiploic pseudomeningocele were selected from the databases of Medline and PubMed. Searching strategy involved the association of text words as follows: “intradiploic”, “pseudomeningocele”, “intraosseus”, “CSF fistula” and “pseudocyst”.

Studies reporting intradiploic (or intraosseous) arachnoid (or leptomeningeal) cysts were excluded.

The selection of studies was individually performed by two authors (GB and ER). The inclusion of uncertain cases was redefined through a consensus discussion. All included studies were reviewed for pertinent patient data.

Discussion

After posterior cranial fossa surgery by craniotomy or craniectomy, the diploic layer of the occipital bone is exposed. A possible cleft in the reconstructed dura may lead to CSF infiltration by a check-valve mechanism between the inner and outer bony tables of the calvaria. This infiltration is sustained by the physiological CSF pulsation but also by morbid factors, such as hydrocephalus, cysts or edema. These factors synergize in determining a “water hammer effect”, which results in the osteolytic cavitation of the diploe until it is completely replaced by the CSF collection. [2, 7, 8] Consequently, CSF slowly thins the bony tables from the inside, increasing their vulnerability to trauma and malformation. On the other hand, in the case of intradiploic arachnoid cysts the setting is different. As a matter of fact, in this scenario there are both a fracture of the inner bony table of the skull and a herniation of the arachnoid membrane through a dural tear. Also in this case, CSF pulsation and intracranial pressure may facilitate this process. [2, 7, 8]

Reviewing the literature, we encountered only six cases of OIP (shown in **Table 1**). [1, 3-6]

In these cases, clinical presentation was heterogeneous. It should be noted that, as a consequence of pseudomeningocele-induced CSF hypotension, orthostatic headache was the most frequently reported symptom (83.3%). Other unusual signs of onset were reported by Placantonakis et al., who described a patient with rhinoliquorrhea as a consequence of CSF flowing from the OIP through the mastoid cells to the Eustachian tube. [1] Mahaney et al. reported about a patient who presented with numbness in the left forearm [3], while a worsening of an attention deficits was described by Giordano et al. [5] Furthermore, Kurzbuch et al. reported about two patients with peripheral paresthesia. [6] The latter symptoms, however, are much more likely to be ascribed to worsening of Chiari I malformation symptomatology.

Five of the six patients (83.3%) underwent foramen magnum decompression surgery for a Chiari malformation type I. The male/female ratio was 1:2 and the mean age at OIP diagnosis was 13.5 ± 5.0 years (range 7-21 years), while the mean time interval between first surgery and OIP diagnosis was 7.5 ± 6.2 years (range 2-19 years). All cases, except one lost at follow-up, recovered with duroplasty surgery. [1, 3-6] In one case ultrasound-guided CSF draining was effective. [6]

Concordantly, our case exhibited only headache on admission, was female, manifested OIP with late onset (12 years from the first surgery) and resolved with a collagen-based dural graft duroplasty and a cranioplasty with acrylic resin. In addition, a probable OIP-promoting factor was present, a vermian cyst resulting from removal of the pilocytic astrocytoma.

In the case of OIP, cranial CT scan demonstrates fluid-filled expansion of the diploic space in the occipital bone but also allows to visualize the craniotomy/craniectomy gap defect, any thinning of both skull tables, and the extent of the CSF collection that may circumferentially vary from the occipital squama alone to the involvement of condyles and clivus. [7] MRI provides more detailed information on the cerebral parenchyma and CSF dynamics, representing a valuable imaging technique for the differentiation from circumscribed osteolytic lesions, such as dermoid cyst, epidermoid cysts, eosinophilic granulomas, aneurysmal bone cysts and metastatic tumors. [7] Intradiploic pseudomeningocele appears as an isointense (in relation to CSF) lesion on both T₁ and T₂-weighted sequences with no enhancement following gadolinium administration. On the other hand, Diffusion-Weighted Imaging (DWI) shows the lesion as hypointense and can be used to differentiate from epidermoid cysts, which appear as high signal intensity [9-11]. Intradiploic arachnoid cyst can be differentiated, in contrast to OIP, by the evident arachnoid lining [12]. Moreover, MRI can identify the coexistence of promoting factors such as hydrocephalus, cysts, or edema in the posterior cranial fossa.

Considering the reported cases, in our opinion, surgical treatment should be adopted even if OIP is accidentally detected in an asymptomatic patient because of its natural tendency towards a slow but progressive enlargement. [5] The major concern is a progressive structural weakening of the skull base, including the occipital condyles, making it more vulnerable, to trauma with possible “ping-pong ball” sinking and instability of the craniocervical junction. The goal of surgery is to seal the dural cleft, aspirate the intradiploic CSF collection and seal the diploe in order to prevent liquor re-infiltration. Theoretically, dural sealing alone interrupts the water hammer mechanism and the progression of bone erosion internally.

Conclusions

Pediatric patients undergoing posterior cranial fossa craniotomy/craniectomy, particularly in the case of foramen magnum decompression, may postoperatively develop a pseudomeningocele with occipital intradiploic CSF infiltration. In this setting, treatment of any dural CSF fistula should be considered because of the risk of progressive extension and bone erosion. Factors such as hydrocephalus, cysts or edema may promote and accelerate the phenomenon and should be treated whenever possible.

Statements and declarations

Statement of Ethics: We confirm that we have read the Journal’s position on issues involved in ethical publication and affirm that this work is consistent with those guidelines. Ethical approval is not required for this study in accordance with local guidelines in view of the retrospective nature of the study and because all the procedures performed were part of the routine care. Informed consent was obtained from all individual participants included in the study. Patient signed informed consent regarding publishing his data and photographs.

Conflict of Interest Statement: The authors have no conflicts of interest to declare that are relevant to the content of this article.

Funding Sources: The authors did not receive support from any organization for the submitted work. **Author**

Contributions: Giulio Bonomo, Giorgio G. Carrabba and Paolo Rampini performed the clinical assessment. Giulio Bonomo, Emanuele Rubiu, Guglielmo Iess, Roberta Bonomo and Alessia Amato critically reviewed the literature and drafted the manuscript. All authors were responsible for important intellectual content. All authors read and approved the final version of the manuscript.

Data Availability Statement: The authors confirm that the data supporting the findings of this study are available within the article. Supplementary materials are available from the corresponding author upon reasonable request for their containing information that could compromise the privacy of research participants.

References

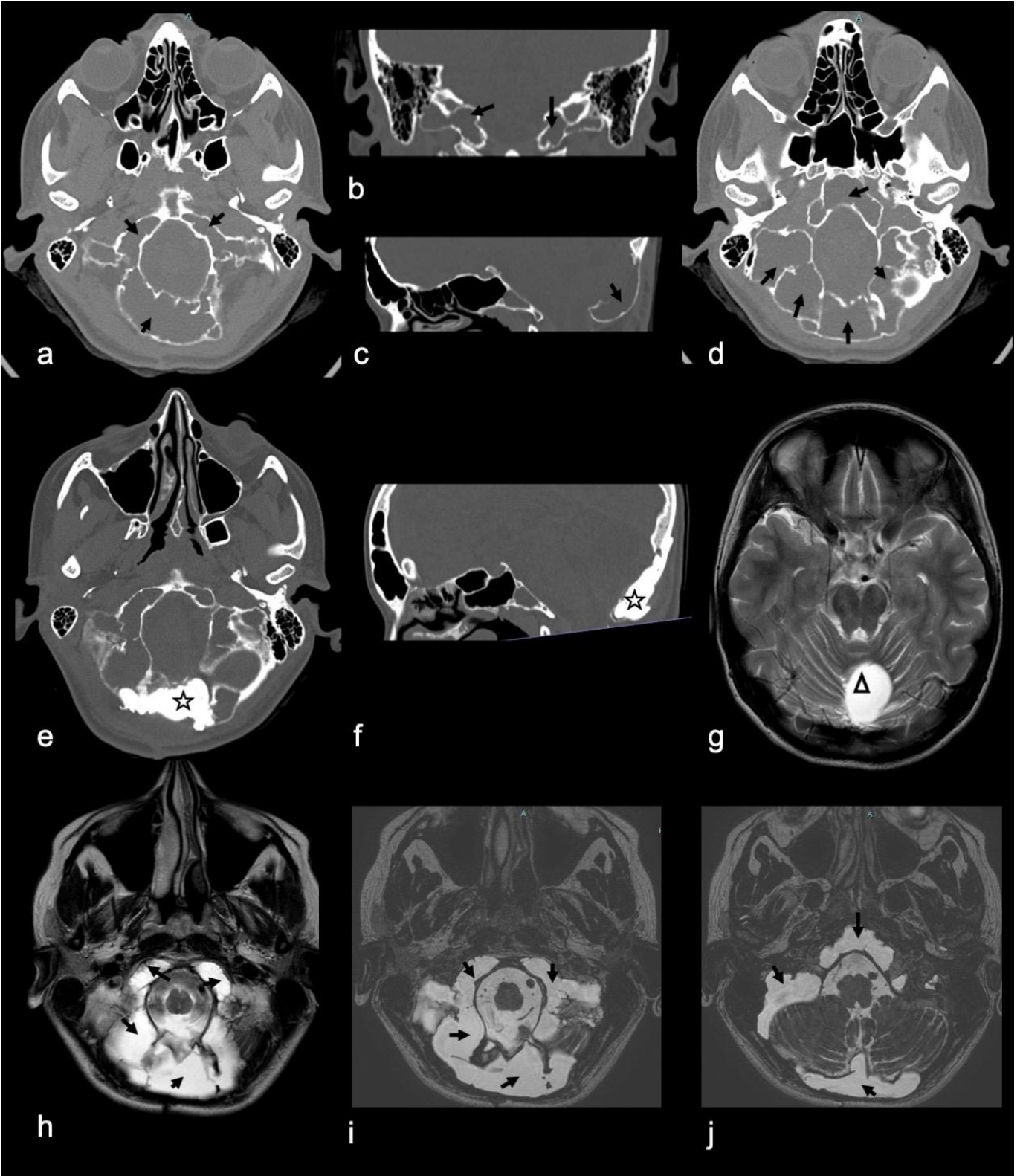
1. Placantonakis DG, Lis E, Souweidane MM. Intradiploic cerebrospinal fluid fistulas of iatrogenic origin. Report of two cases. *J Neurosurg.* 2006 May;104(5 Suppl):356-9. doi: 10.3171/ped.2006.104.5.356. PMID: 16848095.

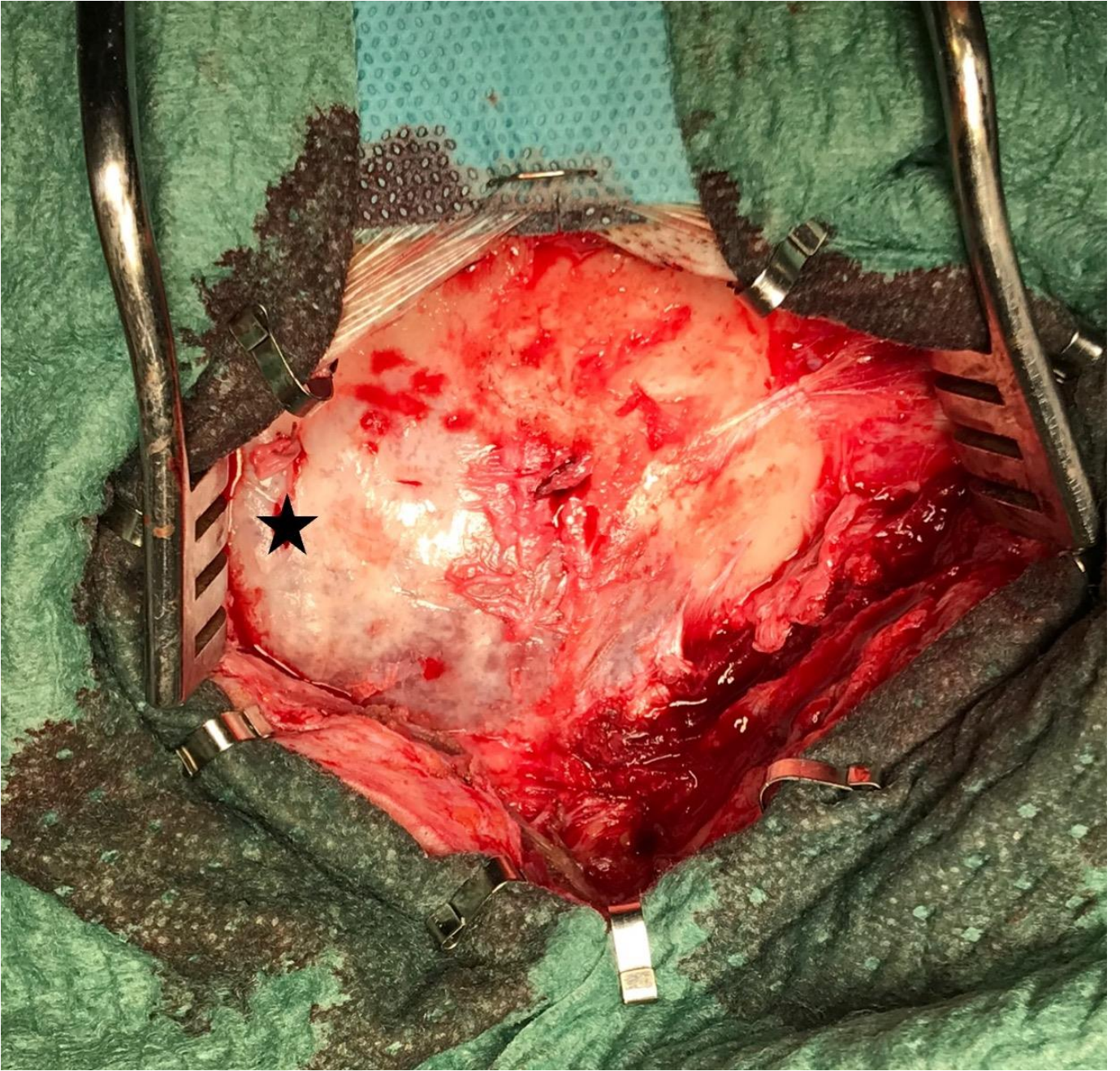
2. Turgut M. Intradiploic arachnoid cyst of the posterior fossa. *Childs Nerv Syst.* 1998 Apr-May;14(4-5):149-50. doi: 10.1007/s003810050199. PMID: 9660112.
3. Mahaney KB, Menezes AH. Intradiploic occipital pseudomeningocele in a patient with remote history of surgical treatment of Chiari malformation. *J Neurosurg Spine.* 2014 Nov;21(5):769-72. doi: 10.3171/2014.6.SPINE13785. Epub 2014 Aug 22. PMID: 25147975.
4. Bulleid LS, Hughes T, Bhatti I, Leach PA. Low-pressure headaches following foramen magnum decompression secondary to absorption of cerebrospinal fluid into the venous system of the diploic space. *Childs Nerv Syst.* 2016 May;32(5):897-9. doi: 10.1007/s00381-015-2928-7. Epub 2015 Oct 7. PMID: 26445976.
5. Giordano M, Di Rocco C. Iatrogenic intradiploic cerebrospinal fluid collection. *Childs Nerv Syst.* 2016 May;32(5):787-90. doi: 10.1007/s00381-016-3037-y. Epub 2016 Feb 11. PMID: 26869055.
6. Kurzbuch AR, Magdum S, Jayamohan J. Intradiploic pseudomeningocele and ossified occipitocervical pseudomeningocele after decompressive surgery for Chiari I malformation: report of two cases and literature review. *Neurosurg Rev.* 2017 Apr;40(2):345-350. doi: 10.1007/s10143-017-0828-x. Epub 2017 Feb 9. PMID: 28185017.
7. Seo BR, Lee JK, Jeong IH, Moon SJ, Joo SP, Kim TS, Kim JH, Kim SH. Post-traumatic intradiploic leptomeningeal cyst of the posterior fossa in an adult. *J Clin Neurosci.* 2009 Oct;16(10):1367-9. doi: 10.1016/j.jocn.2008.10.018. Epub 2009 Jun 24. PMID: 19556133.
8. Sato TS, Moritani T, Hitchon P. Occipital intradiploic CSF pseudocyst: an unusual complication of a ventriculoperitoneal shunt malfunction. *AJNR Am J Neuroradiol.* 2009 Mar;30(3):635-6. doi: 10.3174/ajnr.A1320. Epub 2008 Oct 14. PMID: 18854442; PMCID: PMC7051420.
9. Yamaguchi S, Hirohata T, Sumida M, Arita K, Kurisu K. Intradiploic arachnoid cyst identified by diffusion-weighted magnetic resonance imaging--case report. *Neurol Med Chir (Tokyo).* 2002 Mar;42(3):137-9. doi: 10.2176/nmc.42.137. PMID: 11936057.
10. Tsuruda JS, Chew WM, Moseley ME, Norman D. Diffusion-weighted MR imaging of the brain: value of differentiating between extraaxial cysts and epidermoid tumors. *AJR Am J Roentgenol.* 1990 Nov;155(5):1059-65; discussion 1066-8. doi: 10.2214/ajr.155.5.2120936. PMID: 2120936.
11. Murakami N, Matsushima T, Kuba H, Ikezaki K, Morioka T, Mihara F, Inamura T, Fukui M. Combining steady-state constructive interference and diffusion-weighted magnetic resonance imaging in the surgical treatment of epidermoid tumors. *Neurosurg Rev.* 1999 Oct;22(2-3):159-62. doi: 10.1007/s101430050055. PMID: 10547022.
12. Tran DDT, Dinh TPH, Nguyen QB, Mai DT, Truong VT. Spontaneous Resolution of Postoperative Giant Frontal Pseudomeningocele. *Asian J Neurosurg.* 2021 May 28;16(2):372-375. doi: 10.4103/ajns.AJNS_18_21. PMID: 34268167; PMCID: PMC8244681.

Figure Legend

Fig. 1. (a) (d) Axial, (b) coronal, (c) sagittal preoperative volumetric computed tomography (CT) scan with bone reconstruction algorithm and axial (h) T2-weighted and (i) (j) Constructive Interference in Steady State (CISS) sequences on preoperative volumetric magnetic resonance imaging (MRI) showing an occipital pseudomeningocele extended intradiploically (**black arrows**) from the squama to the condylar and clival regions, thinning both occipital bone tables and dilating the CSF-filled diploe. (g) Axial T2-weighted sequences on preoperative volumetric MRI showing a vermian cyst (**triangle**), resulting from the surgical removal of the pilocytic astrocytoma. (e) Axial and (f) sagittal postoperative volumetric CT scan with bone reconstruction algorithm showing occipital cranioplasty with acrylic resin (**star**).

Fig. 2. Intraoperative image after exposure of lateral suboccipital craniotomy demonstrating the “blown-glass” appearance (**star**) of the occipital squama.





ACCEPT

Authors	Year of Publication	Primary disease	Type of surgical intervention	Age at OIP diagnosis	Type of corrective surgery	Interval between first surgery and OIP	Gender	Symptoms	Outcome
Placantonakis et al. [1]	2006	Medulloblastoma	Craniotomy	16 years	Resection of recurrent tumor and fat allograft with fibrin sealant	9 years	F	Rhinoliquorrhea	Resolution
Mahaney et al. [3]	2014	Chiari I malformation	Suboccipital Median Craniectomy	21 years	Duroplasty with fascia lata allograft followed by on lay of Durepair and DuraGen	19 years	F	Numbness in the left forearm and headache	Resolution
Bulleid et al. [4]	2015	Chiari I malformation	Suboccipital Median Craniectomy (Foramen Magnum decompression)	14 years	Dural patch with DuraGen and Tisseal Glue	5 years	M	Headache and visual disturbance	Resolution
Giordano et al. [5]	2016	Chiari I malformation	First surgery: Occipital bone decompression Second surgery: intracranial approach with partial cerebellar tonsil excision and enlarging duroplasty	14 years	New enlarging duroplasty	2 years	M	Headache and worsening attention deficits	Resolution
Kurzbuch et al. [6]	2017	Chiari I malformation	Suboccipital decompressive surgery and partial resection of the posterior arch of C1	7 years	Not done	3 years	F	Headache and paresthesia in all four limbs	Lost at follow-up
Kurzbuch et al. [6]	2017	Chiari I malformation	Suboccipital decompressive surgery and partial resection of the posterior arch of C1	9 years	Ultrasound-guided CSF draining	7 years	F	Headache and paresthesia in upper arms	Resolution

Bonomo et al.	2022	Cerebellar Pilocytic Astrocytoma	Suboccipital Lateral Craniotomy	18 years	Watertight duroplasty with collagen- based dural graft and cranioplasty with acrylic resin	12 years	F	Headache	Resolution
------------------	------	--	---------------------------------------	----------	---	----------	---	----------	------------

Table 1. Literature review of reported cases of intradiploic pseudomeningoceles.

Accepted Manuscript